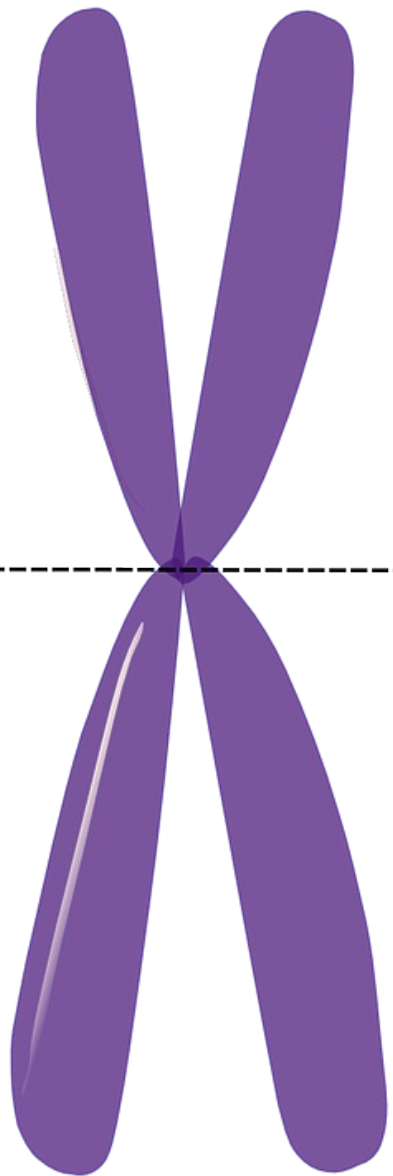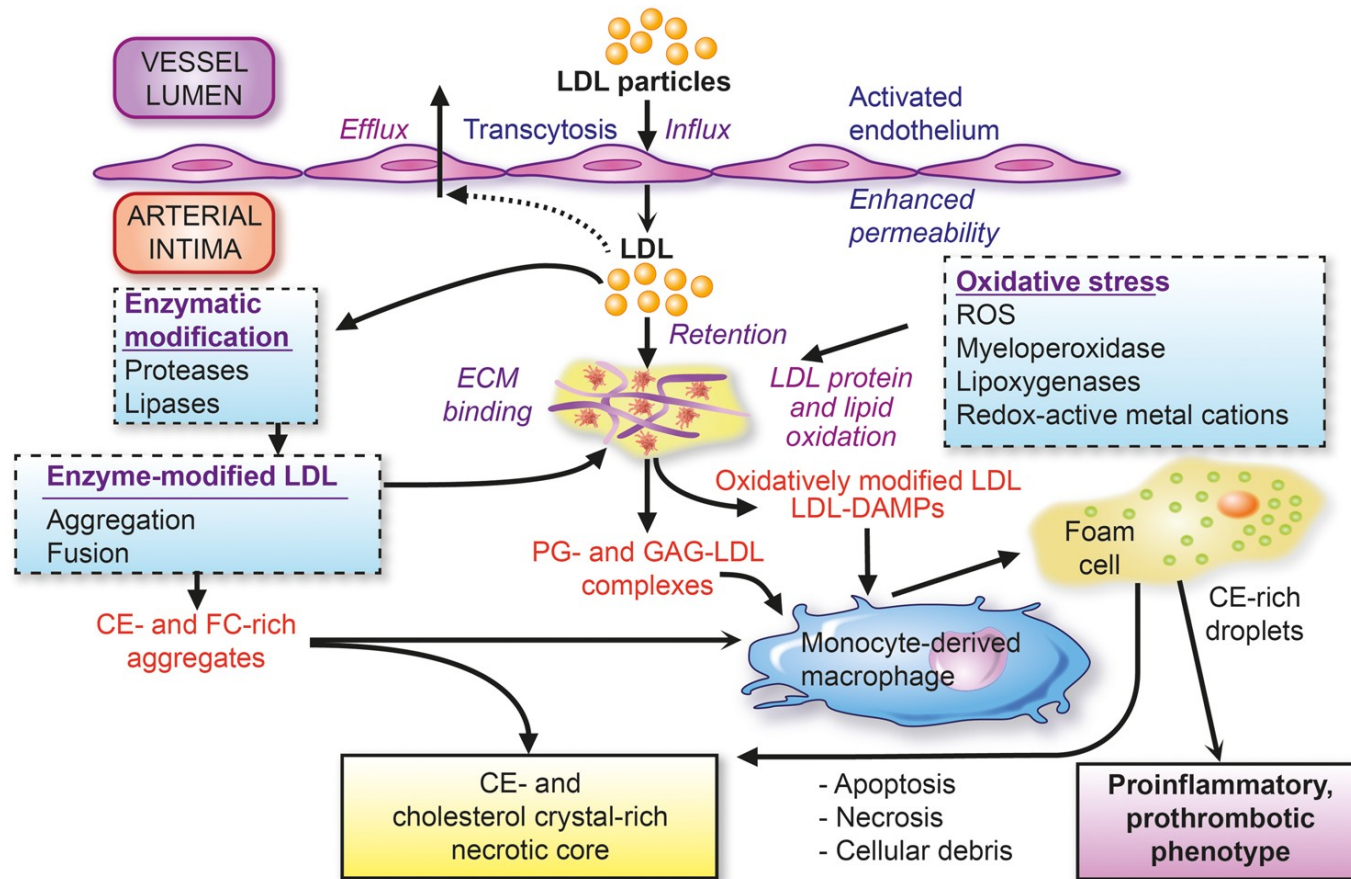
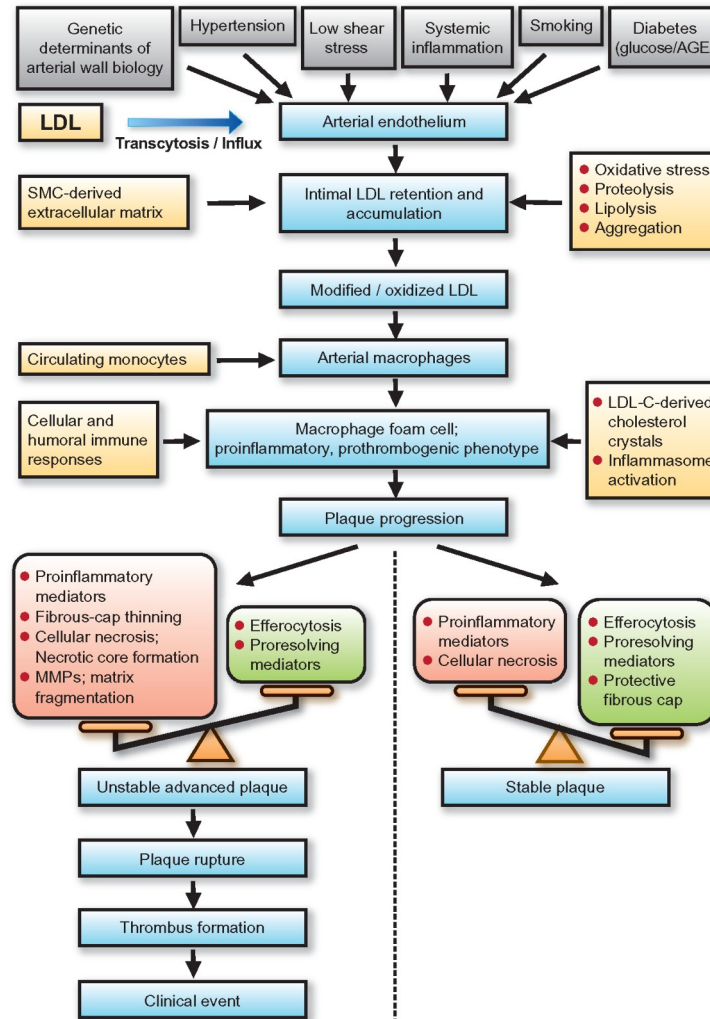


Figure 1 Low-density lipoprotein (LDL) as the primary driver of atherogenesis. Key features of the influx and ...



Take home figure Low-density lipoprotein (LDL) and atherobiology.
Summary of the principal mechanisms underlying the entry, ...



Retrieval Practise



KNOW THE
RULES



Best Effort!



No talking



Assess yourself

Nailed it



Not sure



Nailed it!

You are
confident about
your answer.



Not sure...

You do not know or
are uncertain.



Ready?

Q01: Terminology

On the next slide, a set of 16 terms will be listed. For each term, mark YES if you know or recognise the term, NO if you don't know the term.

Yes = I recognise the term

No = I have no idea at all

Q01: Yes or No

1. Lumen
2. Low Density Lipoprotein
3. Endothelium
4. Intima
5. Extracellular matrix
6. Monocyte
7. Macrophage
8. Apoptosis
9. Necrosis
10. Hypertension
11. Arterial wall
12. Smoking
13. Diabetes
14. Smooth muscle cell
15. Plaque
16. Thrombus

Question

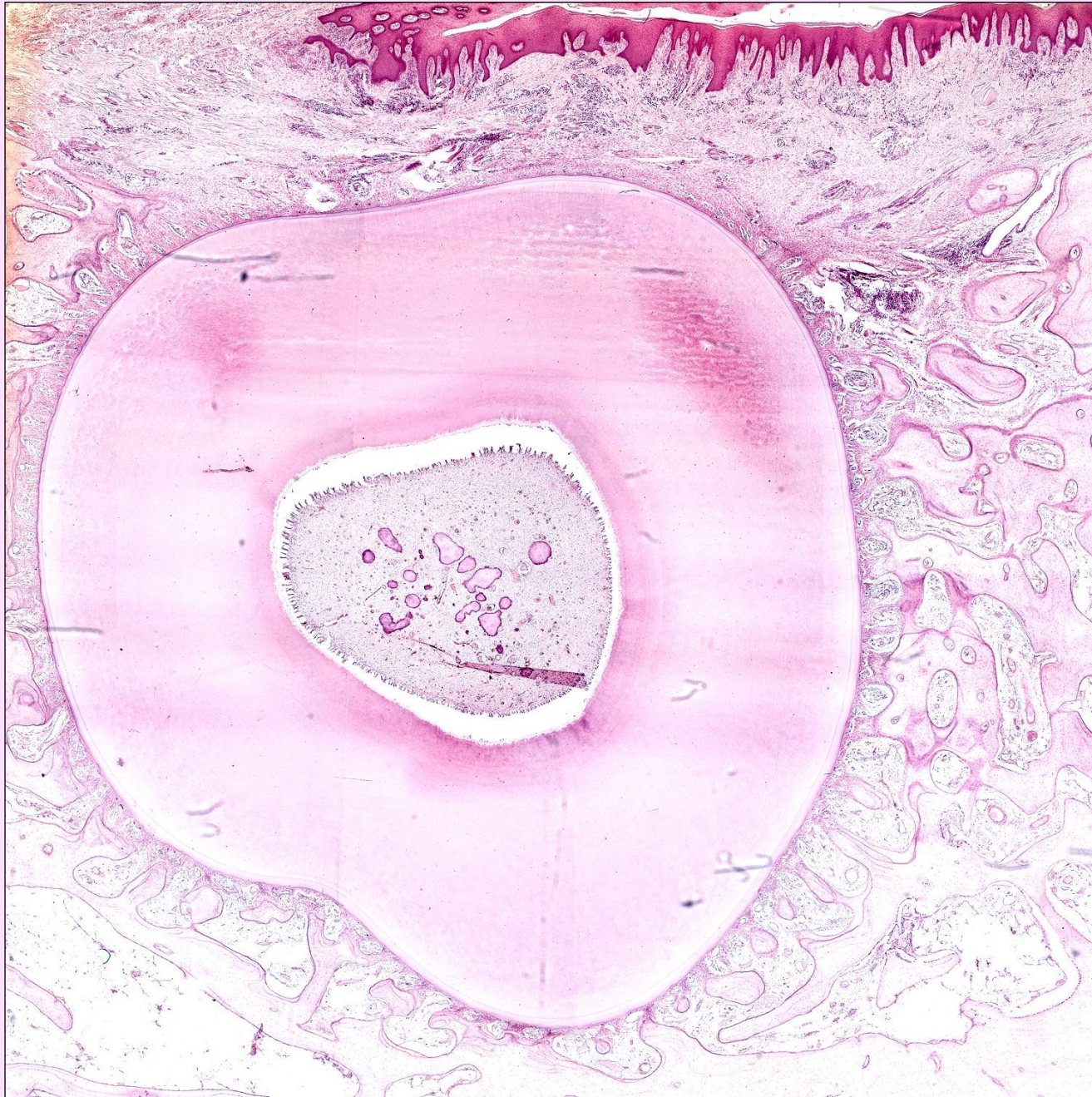
True/False

I am susceptible to breast cancer

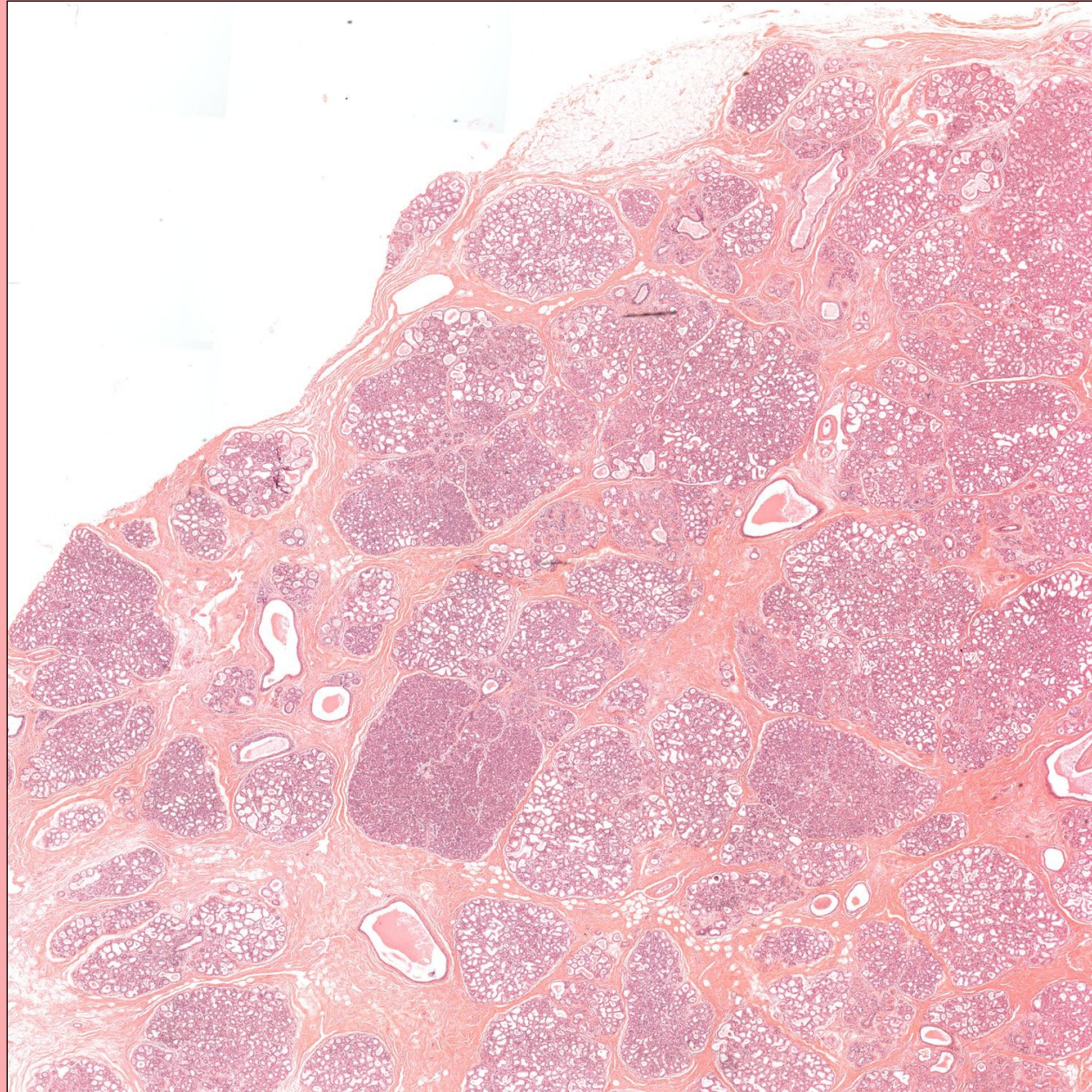
Question:

1. List 2 types of exocrine secretions.
2. List 3 ways substances are secreted from cells.
3. What epithelium are associated with ducts?

Q04: Identify the structure.



Q05: Identify the gland.



Q06: Epithelium

1. Is bordered by a _____.
2. Rests on a _____.

FINISH

Assess yourself



Community of Truth

what is my answer?

what is the correct answer?

I am am wrong, what was my error?

THUS: Find the truth

Q01: Yes or No

1. Lumen

2. Low Density
Lipoprotein

3. Endothelium

4. Intima

5. Extracellular matrix

6. Monocyte

7. Macrophage

8. Apoptosis

9. Necrosis

10. Hypertension

11. Arterial wall

12. Smoking

13. Diabetes

14. Smooth muscle cell

15. Plaque

16. Thrombus

9 of 16 = histology

will we ever need to look at slides?

The practical supplies the visual side of the "theoretical" component, and should not be seen as 2 separate topics that should be studied as 2 "subjects".

The slides should be used to expand on your lecture.

Question:

True for everyone

Both women AND men are susceptible to breast cancer.

Breast cancer

of all diagnosed breast cancers:

- Women 99%
- Men 1% (SA = one of the highest in the world)
- 2nd most common type
- 1st = non-melanoma skin cancer



**THE BIG 5 CANCERS
AFFECTING WOMEN IN SA**

BREAST CANCER



No 2 **THE BIG 5 CANCERS**
AFFECTING WOMEN IN SA
CERVICAL CANCER



№ 3 THE BIG 5 CANCERS
AFFECTING WOMEN IN SA
COLORECTAL CANCER



THE BIG 5 CANCERS AFFECTING WOMEN IN SA UTERINE CANCER



**THE BIG 5 CANCERS
AFFECTING WOMEN IN SA
LUNG CANCER**



**THE BIG 5 CANCERS
AFFECTING MEN IN SA
PROSTATE CANCER**



**THE BIG 5 CANCERS
AFFECTING MEN IN SA
COLORECTAL CANCER**



**THE BIG 5 CANCERS
AFFECTING MEN IN SA**

LUNG CANCER



**THE BIG 5 CANCERS
AFFECTING MEN IN SA**

KAPOSI SARCOMA



**THE BIG 5 CANCERS
AFFECTING MEN IN SA
BLADDER CANCER**

A large, light blue male symbol icon (a circle with an arrow pointing up and to the right) is positioned on the left side of the image. It is partially overlapping the first few letters of the word "TESTICULAR".

TESTICULAR CANCER

Question – 1

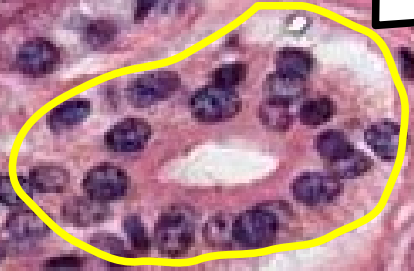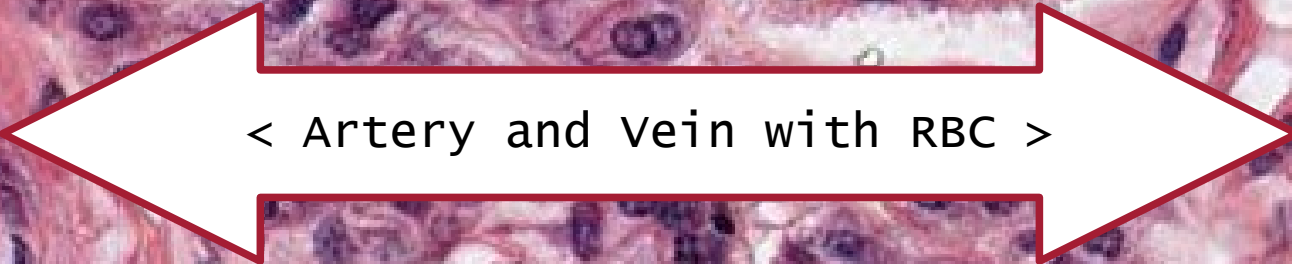
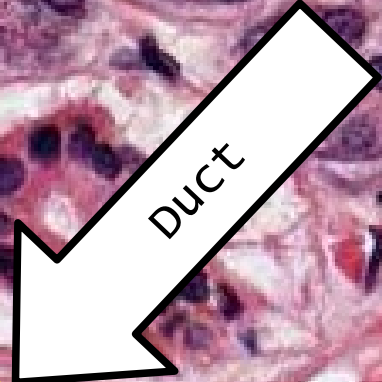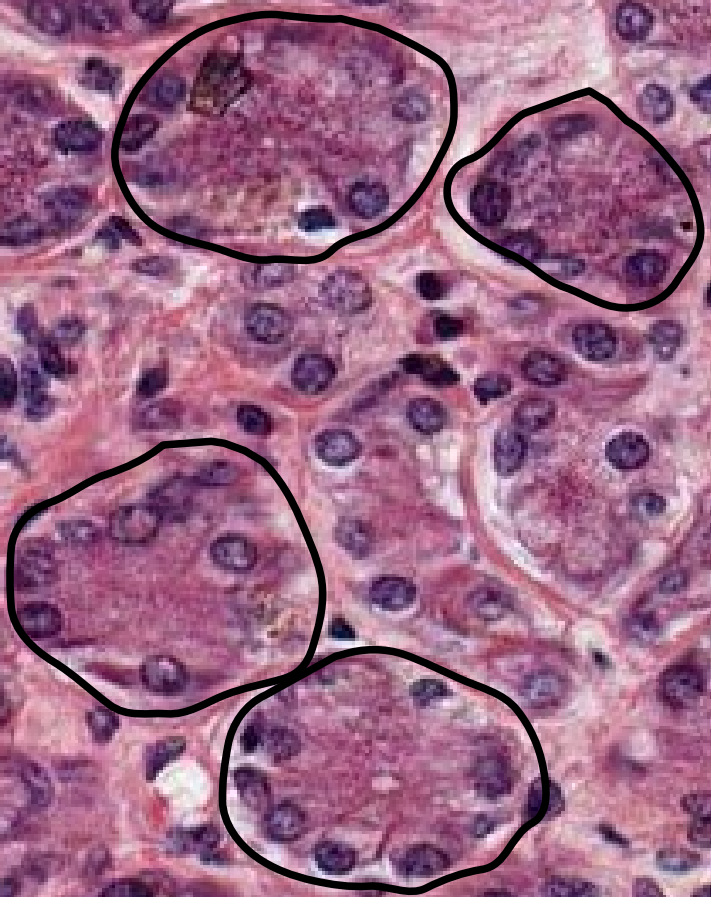
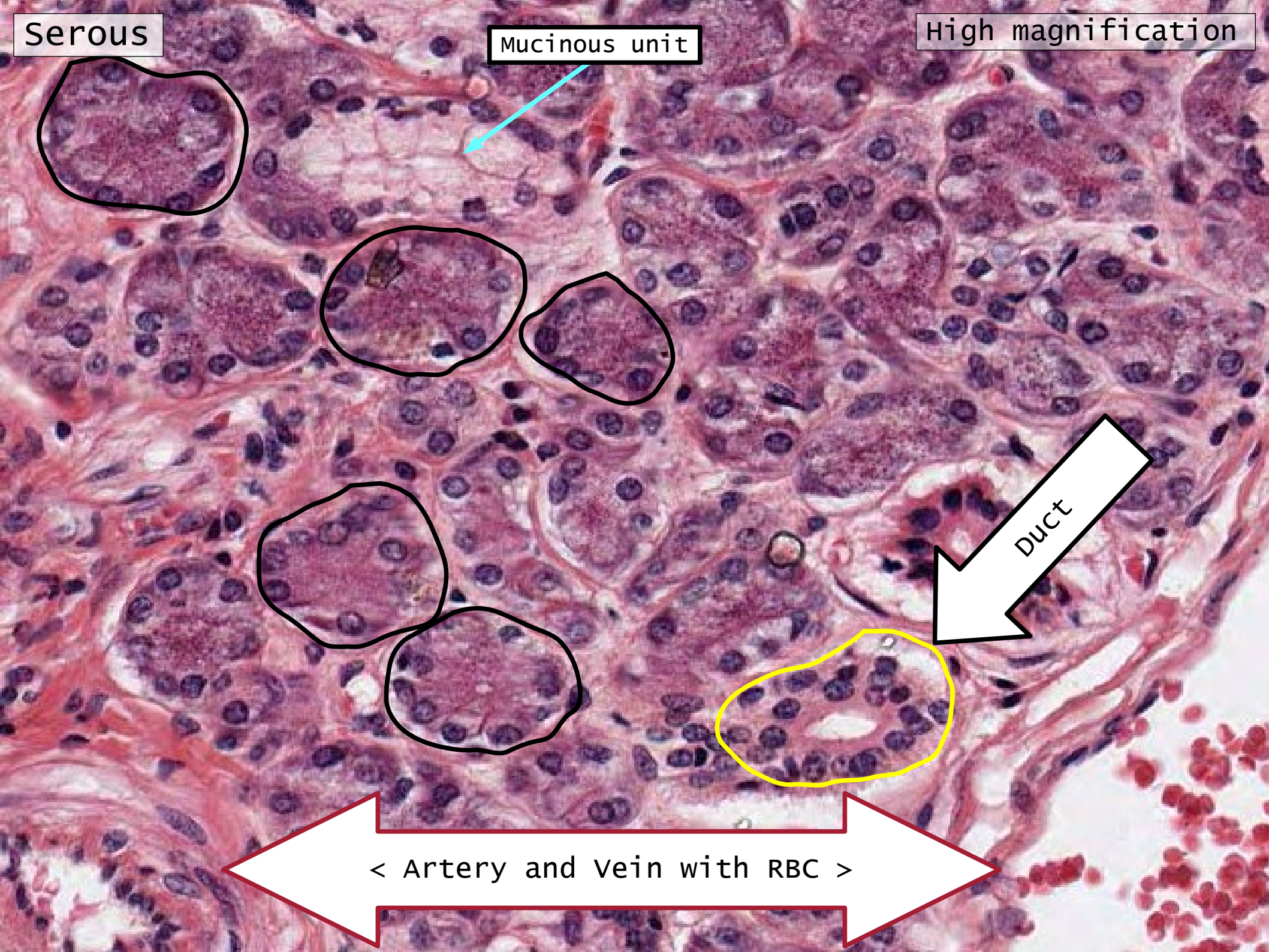
List 2 types of exocrine secretions:

1. Serous
2. Mucinous

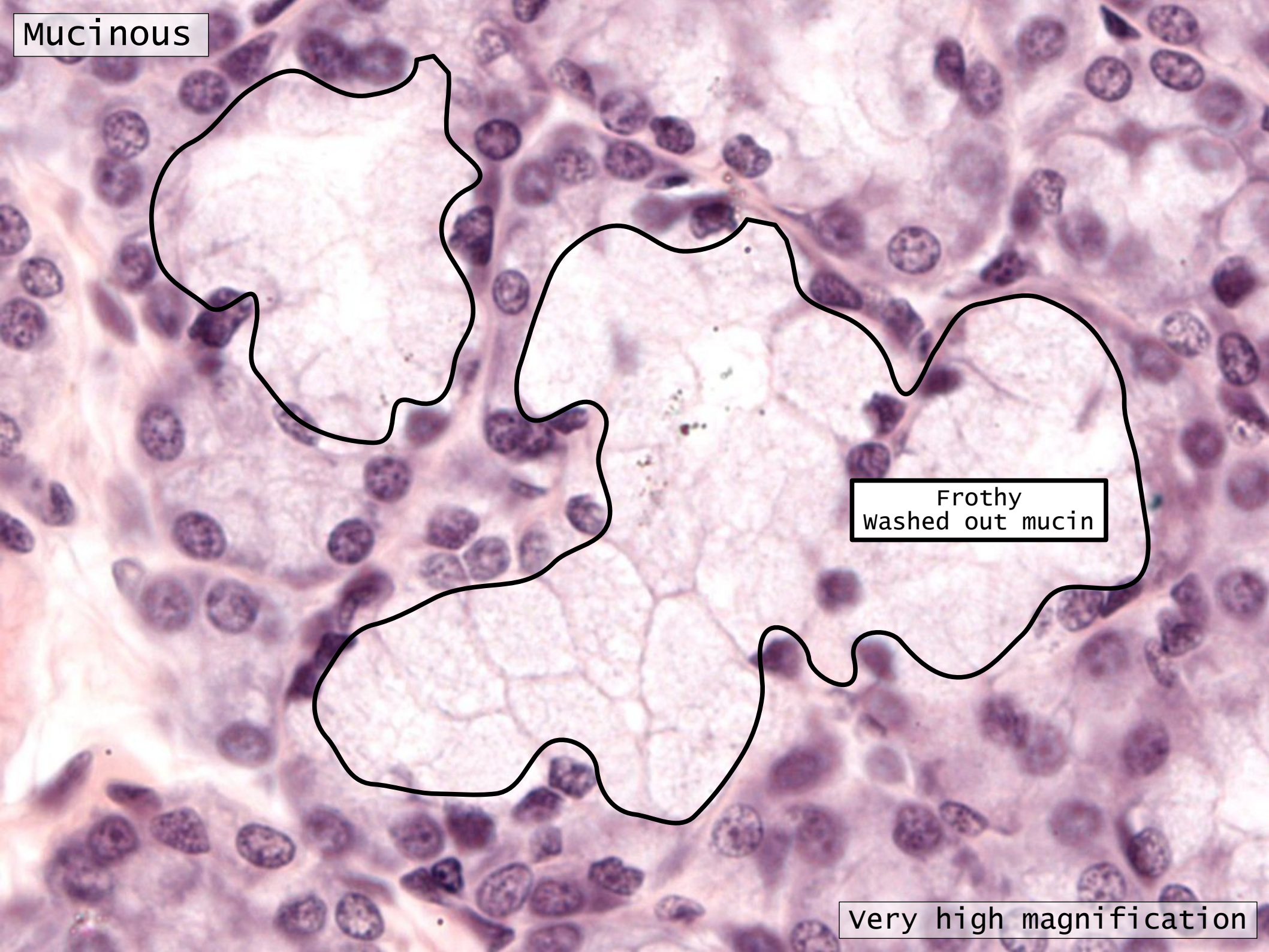
Serous

Mucinous unit

High magnification



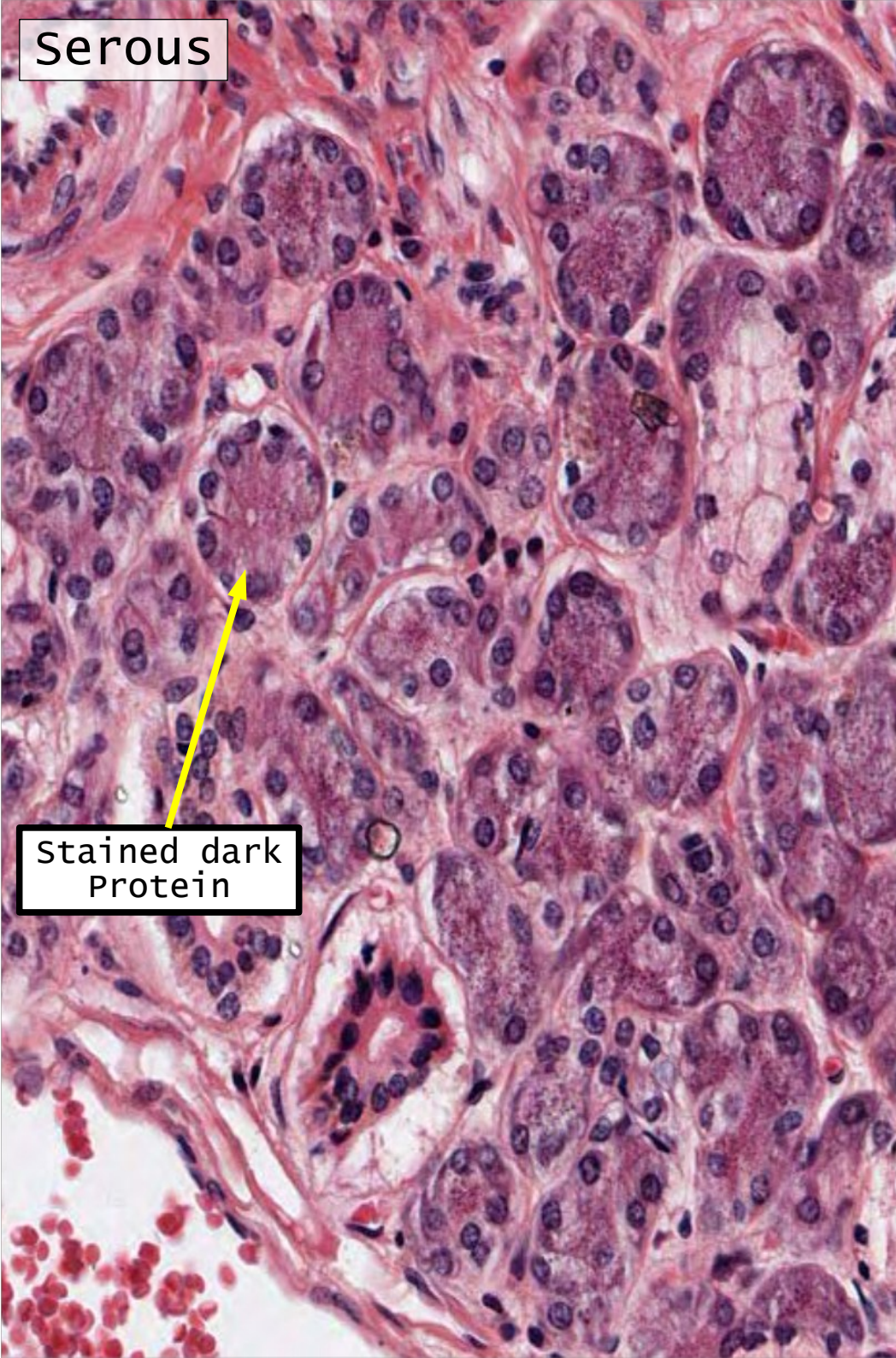
Mucinous



Frothy
washed out mucin

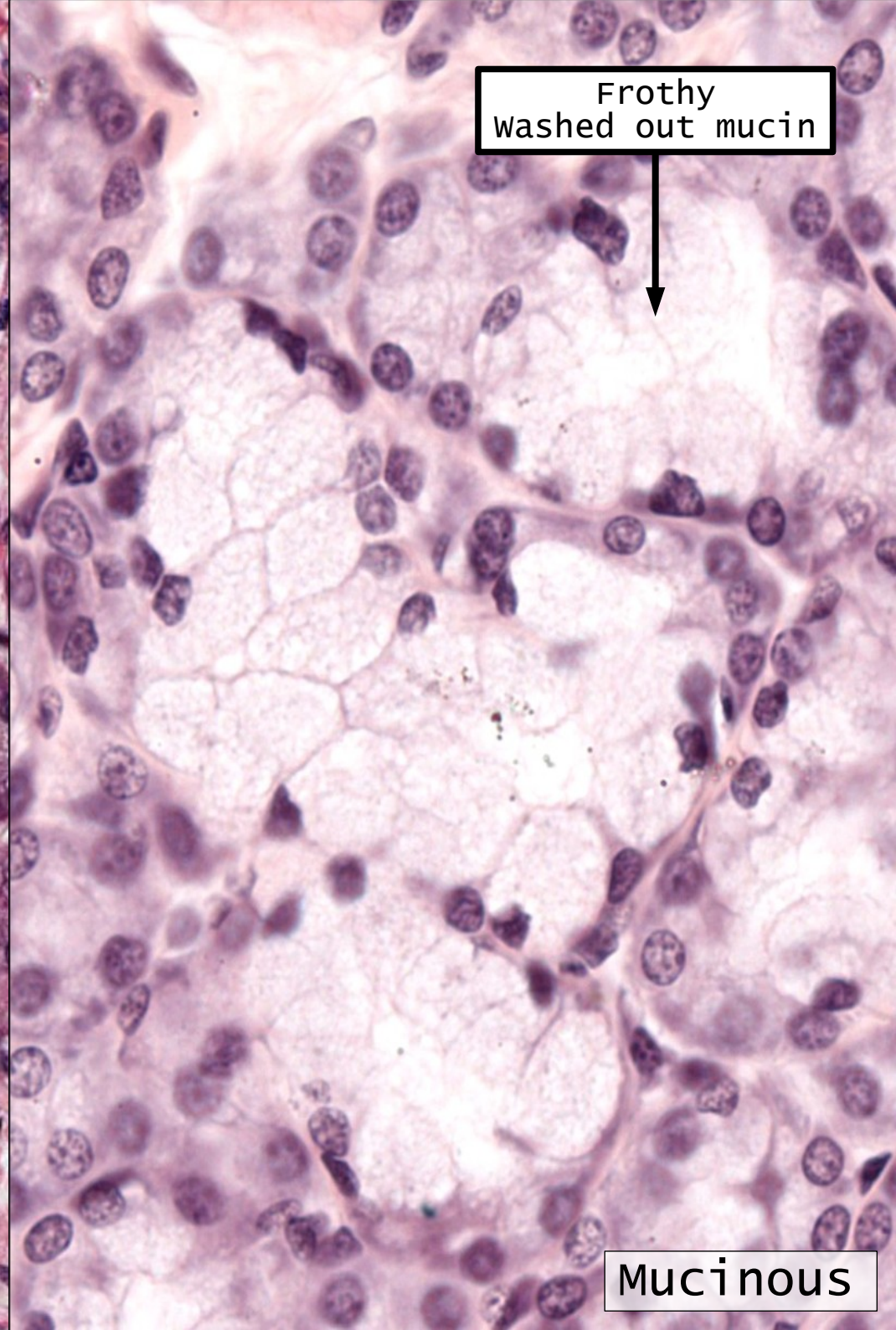
very high magnification

Serous



Stained dark Protein

Frothy washed out mucin



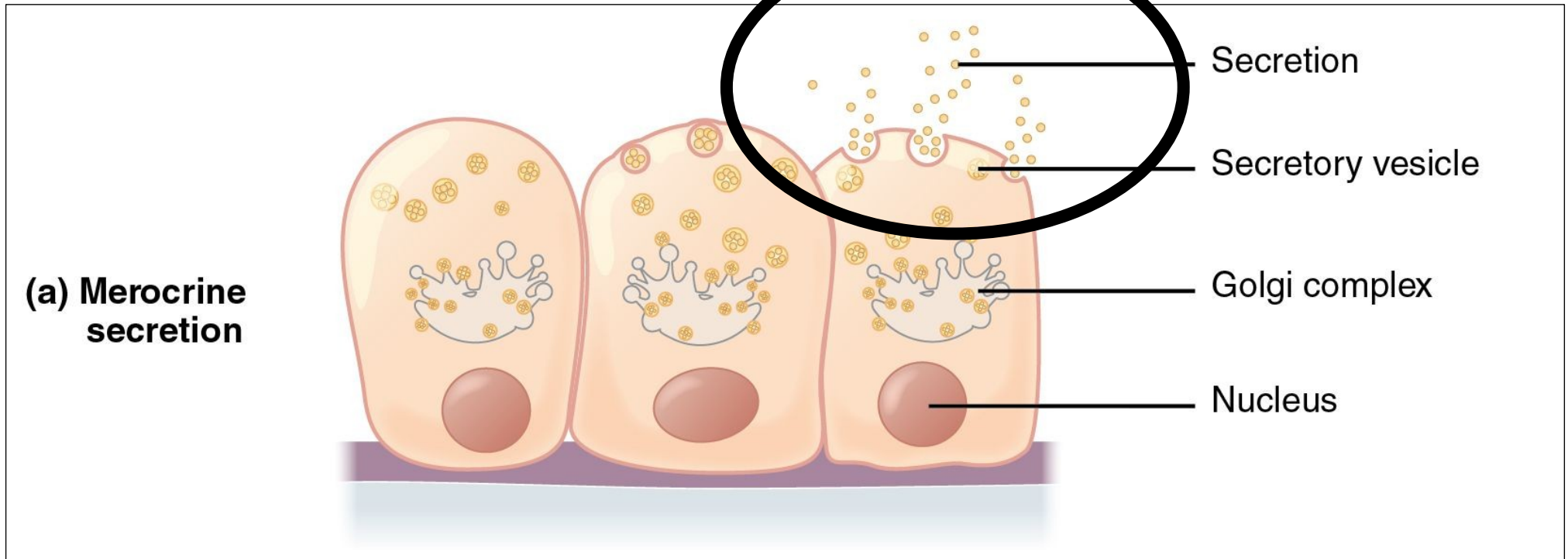
Mucinous

Question – 2

List 3 ways substances are secreted from cells.

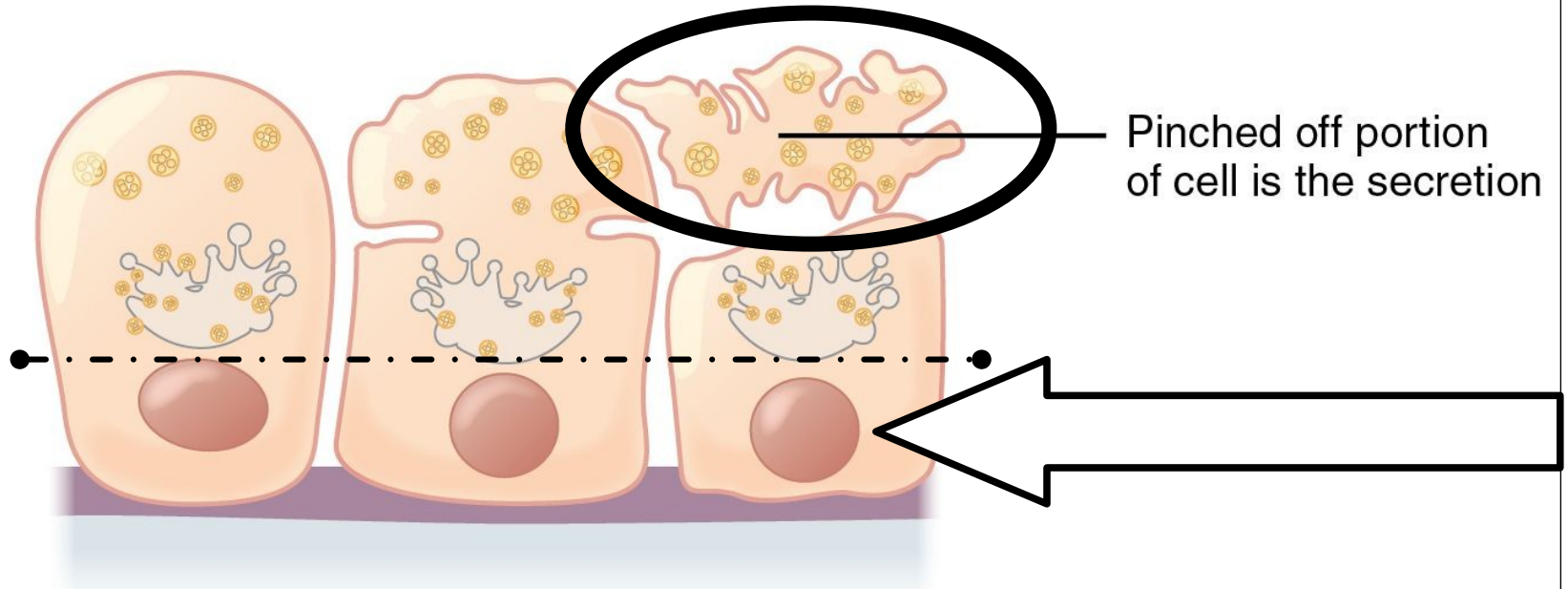
1. Merocrine
2. Apocrine
3. Holocrine

Merocrine



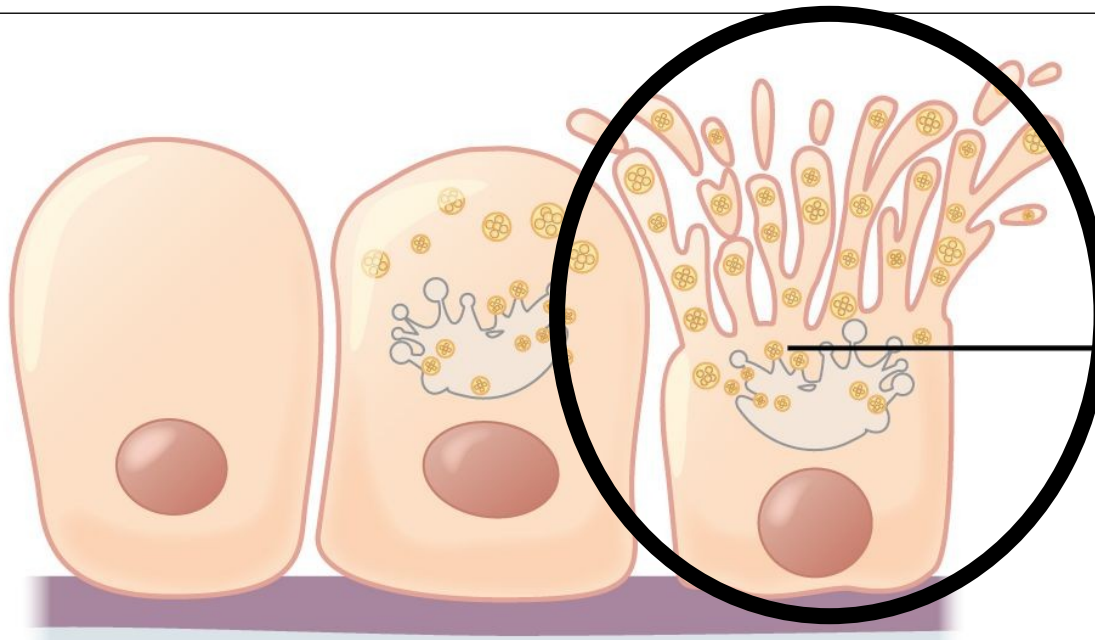
Apocrine

(b) Apocrine secretion



Holocrine

(c) Holocrine secretion



Mature cell dies and becomes secretory product

Question – 3

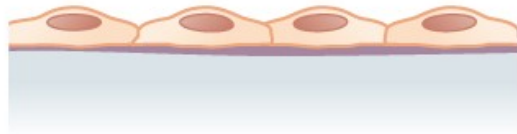
What epithelium are associated with ducts?

1. Cuboidal epithelium

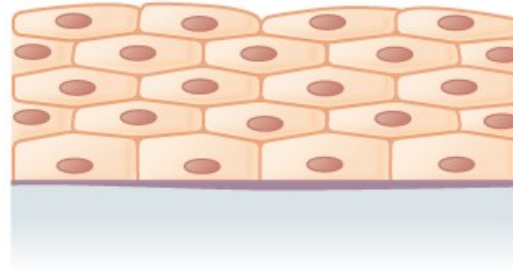
Simple

Stratified

Squamous

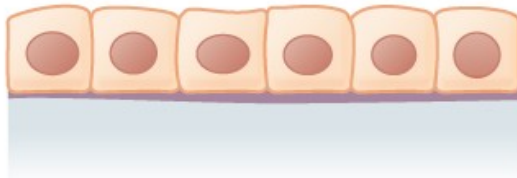


Simple squamous epithelium

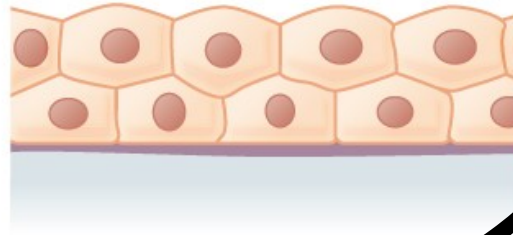


Stratified squamous epithelium

Cuboidal




Simple cuboidal epithelium



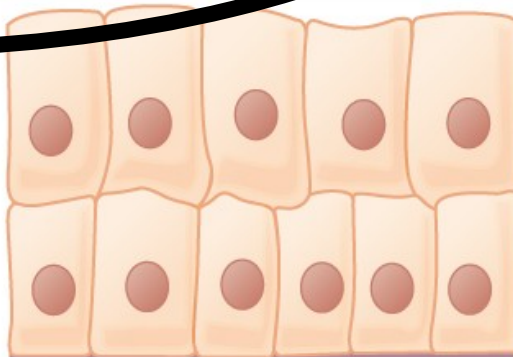
Stratified cuboidal epithelium

Pseudostratified

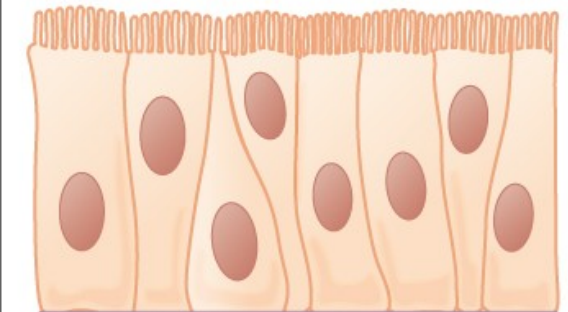
Columnar



Simple columnar epithelium

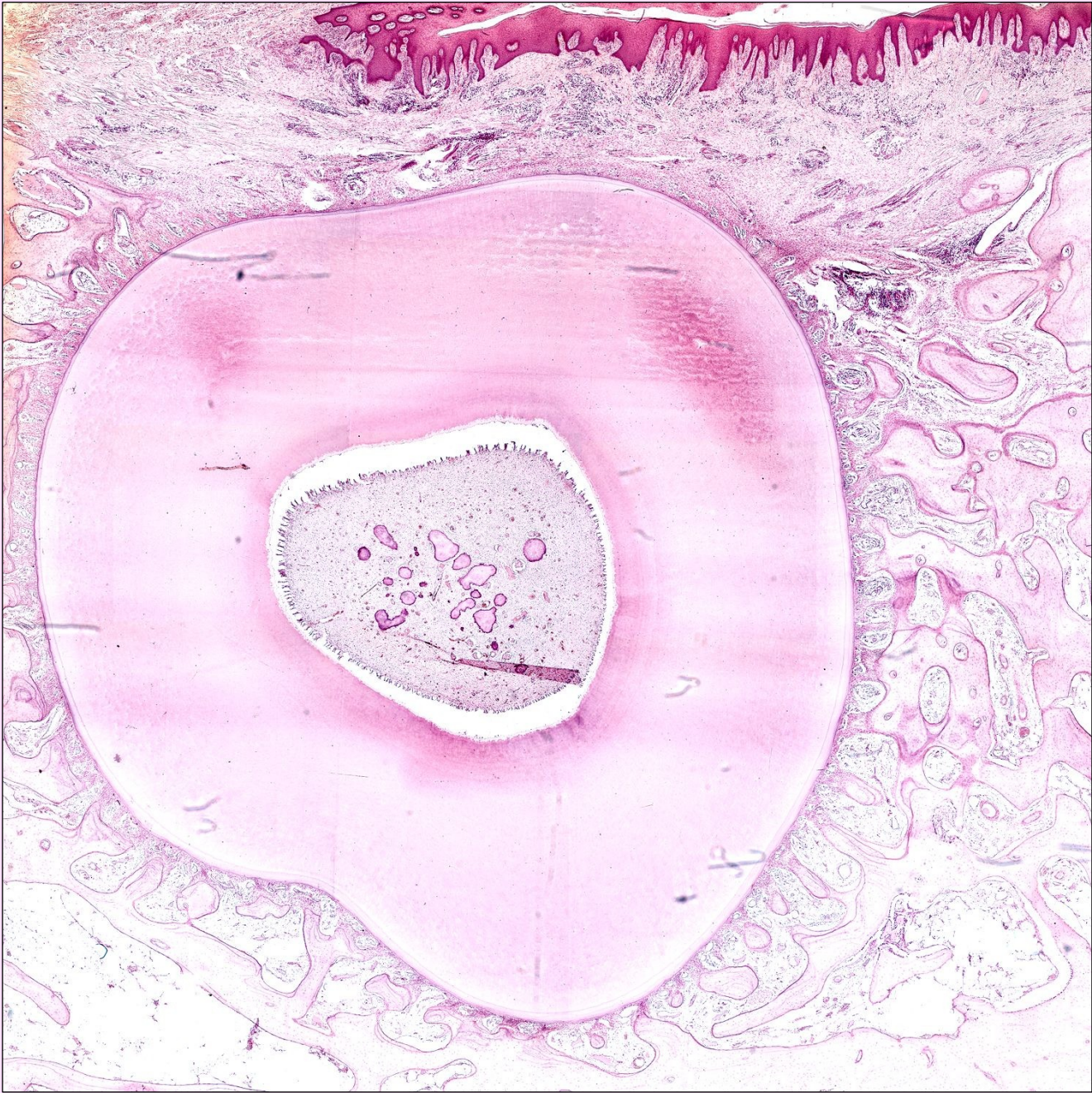


Stratified columnar epithelium

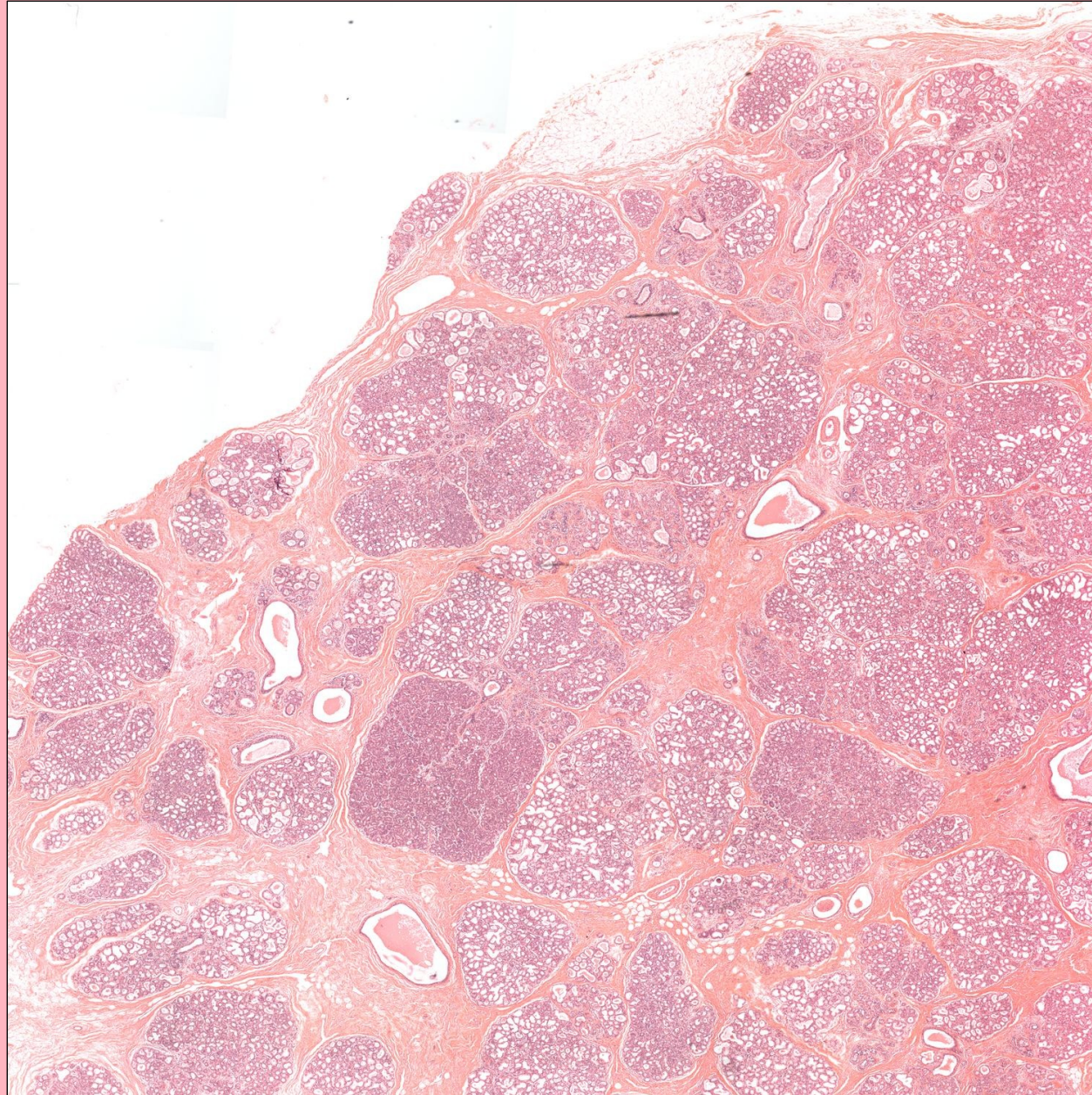


Pseudostratified columnar epithelium

Q04: Cross section of a tooth



Q05 : Mammary gland.



Q06: Epithelium

1. Is bordered by a lumen.
2. Rests on a basement membrane.

Reflection

Are you happy with your performance?

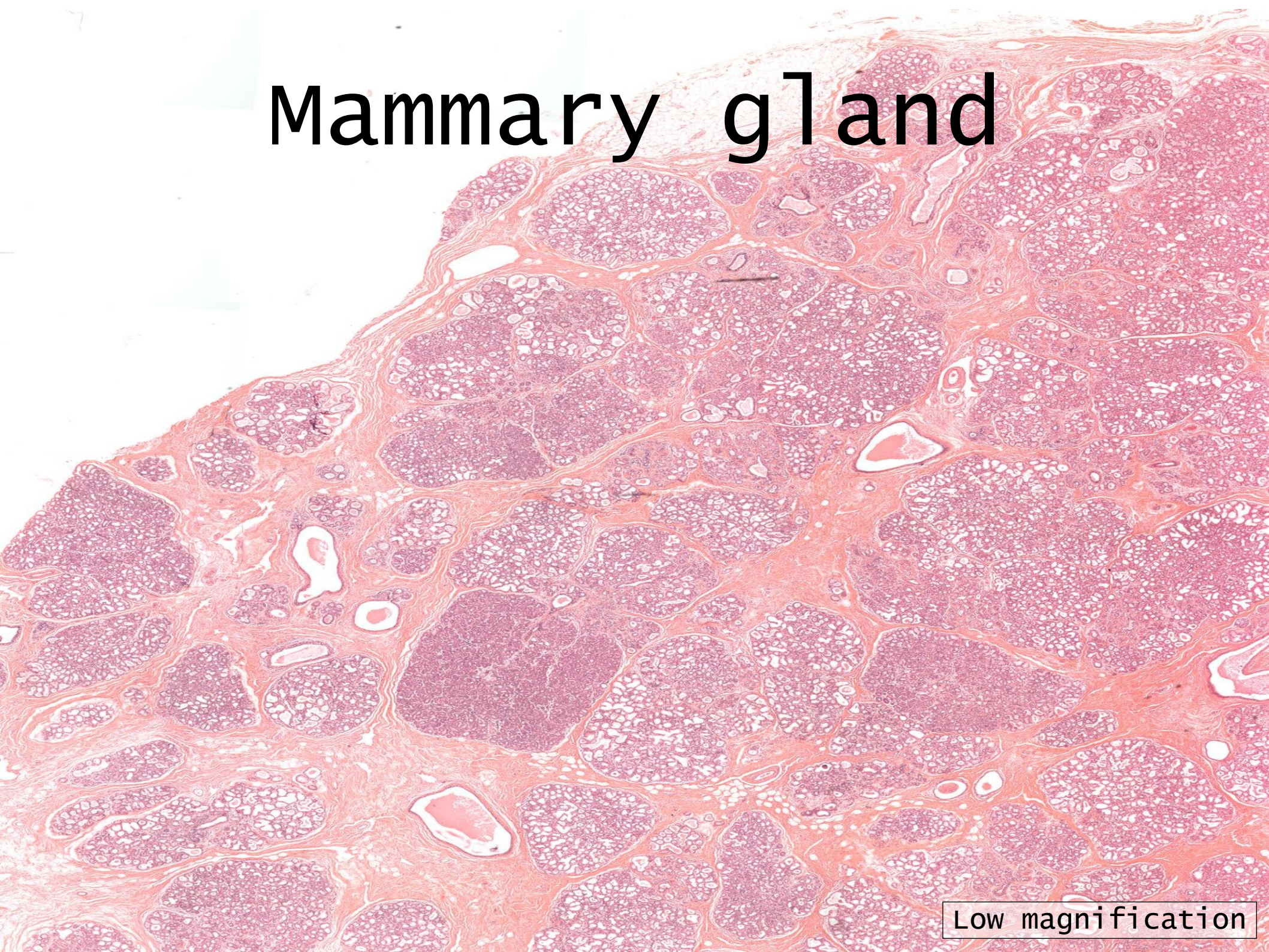


Block 8

4 sessions

- Mammary gland and nipple
- Oral cavity
- Alimentary canal
- Glands

Mammary gland



Low magnification

Mammary gland

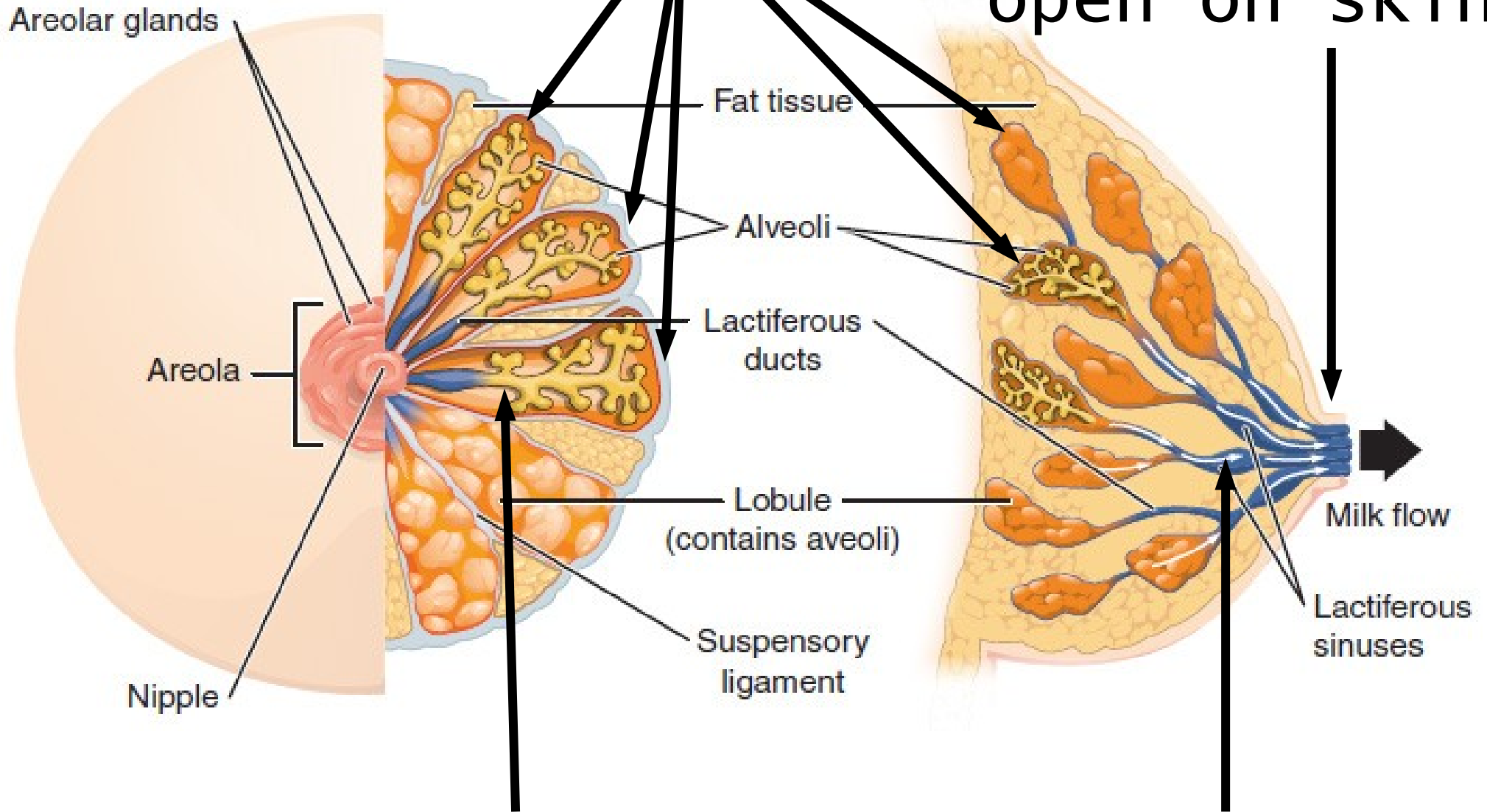
- Compound tubuloalveolar gland
- 12 – 20 glands
- Each with own lactiferous duct
- Each with own lactiferous sinus
- Opens on skin at apex of nipple

Structure of the Lactating Breast

Mammary glands are modified sweat glands. The non-pregnant and non-lactating female breast is composed primarily of adipose and collagenous tissue, with mammary glands making up a very minor proportion of breast volume. The mammary gland is composed of milk-transporting lactiferous ducts, which expand and branch extensively during pregnancy in response to estrogen, growth hormone, cortisol, and prolactin. Moreover, in response to progesterone, clusters of breast alveoli bud from the ducts and expand outward toward the chest wall. Breast alveoli are balloon-like structures lined with milk-secreting cuboidal cells, or lactocytes, that are surrounded by a net of contractile myoepithelial cells. Milk is secreted from the lactocytes, fills the alveoli, and is squeezed into the ducts. Clusters of alveoli that drain to a common duct are called lobules; the lactating female has 12-20 lobules organized radially around the nipple. Milk drains from lactiferous ducts into lactiferous sinuses that meet at 4 to 18 perforations in the nipple, called nipple pores. The small bumps of the areola (the darkened skin around the nipple) are called Montgomery glands. They secrete oil to cleanse the nipple opening and prevent chapping and cracking of the nipple during breastfeeding.

15 - 20 glands

open on skin



lactiferous duct

lactiferous sinus

Two stages

- Resting
- Active

Resting gland

- Connective tissue dominate
- More adipose tissue
- Glandular tissue reduced

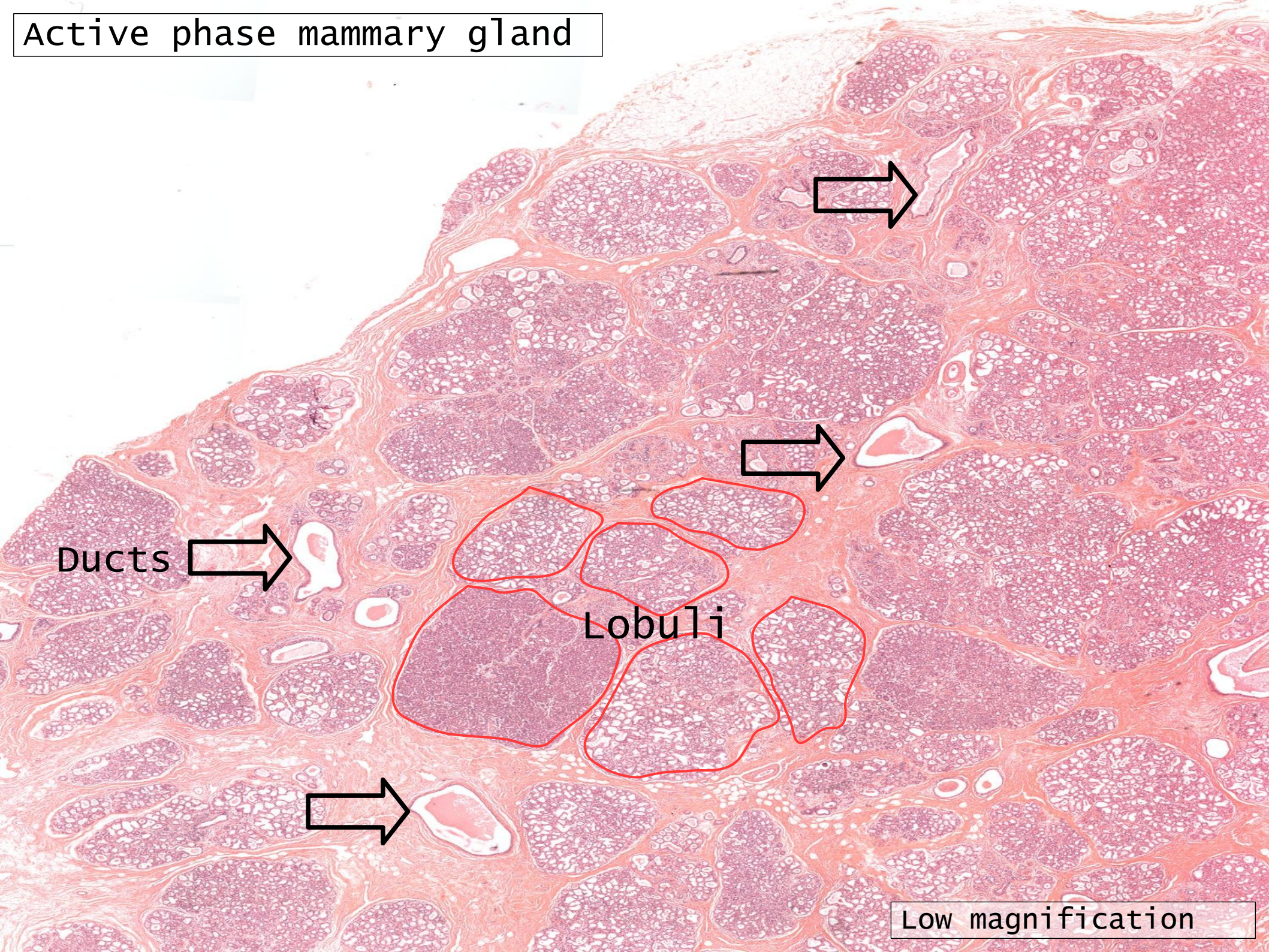
Active gland

- Terminal ducts expand
- Forms alveoli
- Connective tissue reduced
- Adipose tissue reduced
- Glandular tissue dominate

Structures

- Lactiferous sinuses
 - Stratified squamous near opening on skin
 - Stratified cuboidal other parts
- Lactiferous ducts
 - Stratified cuboidal
- Myoepithelial cells
 - Underlie lactiferous ducts in most areas
 - Basal lamina
 - Separate epithelial components from stroma

Active phase mammary gland

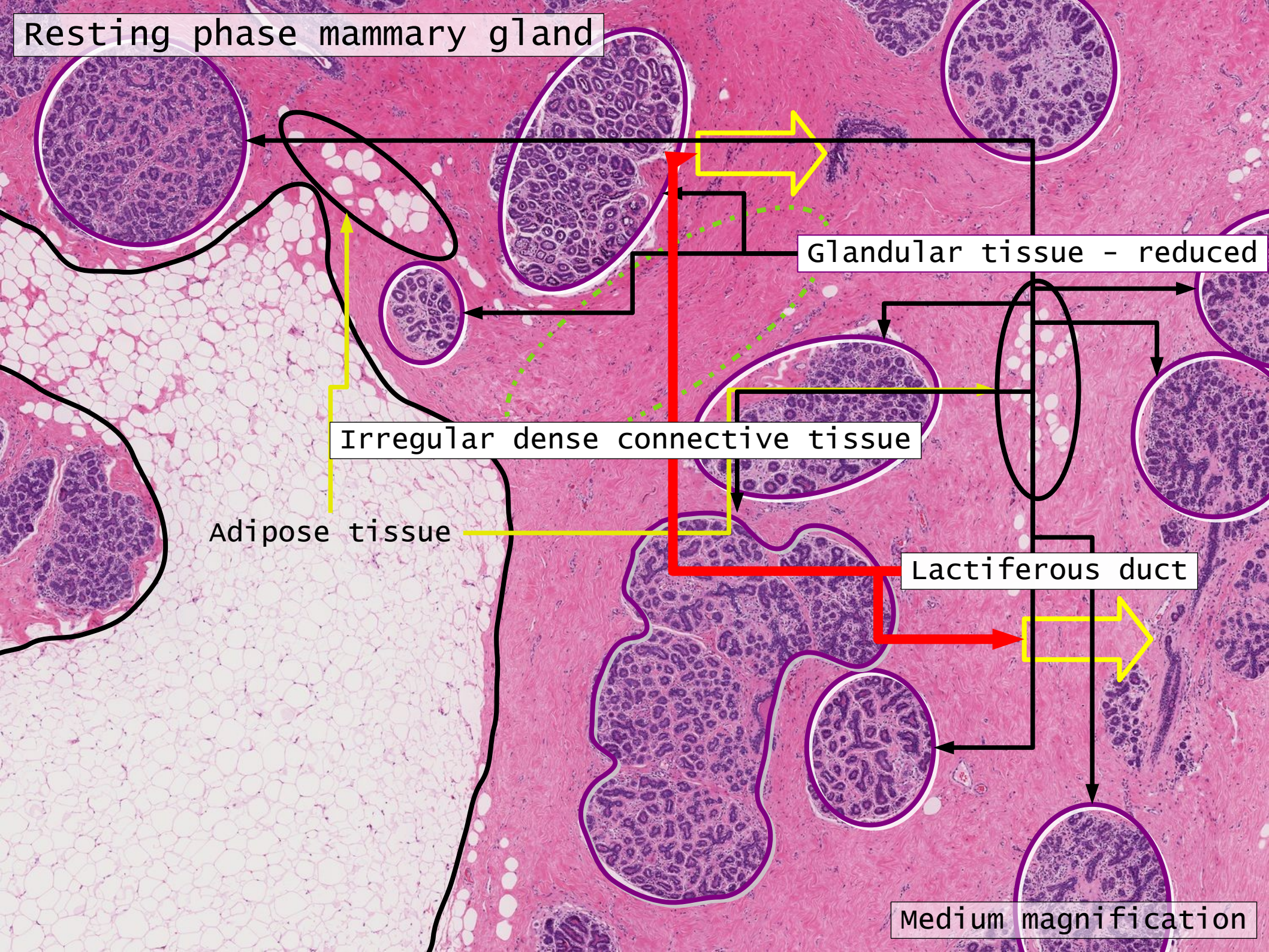


Ducts

Lobuli

Low magnification

Resting phase mammary gland



Glandular tissue - reduced

Irregular dense connective tissue

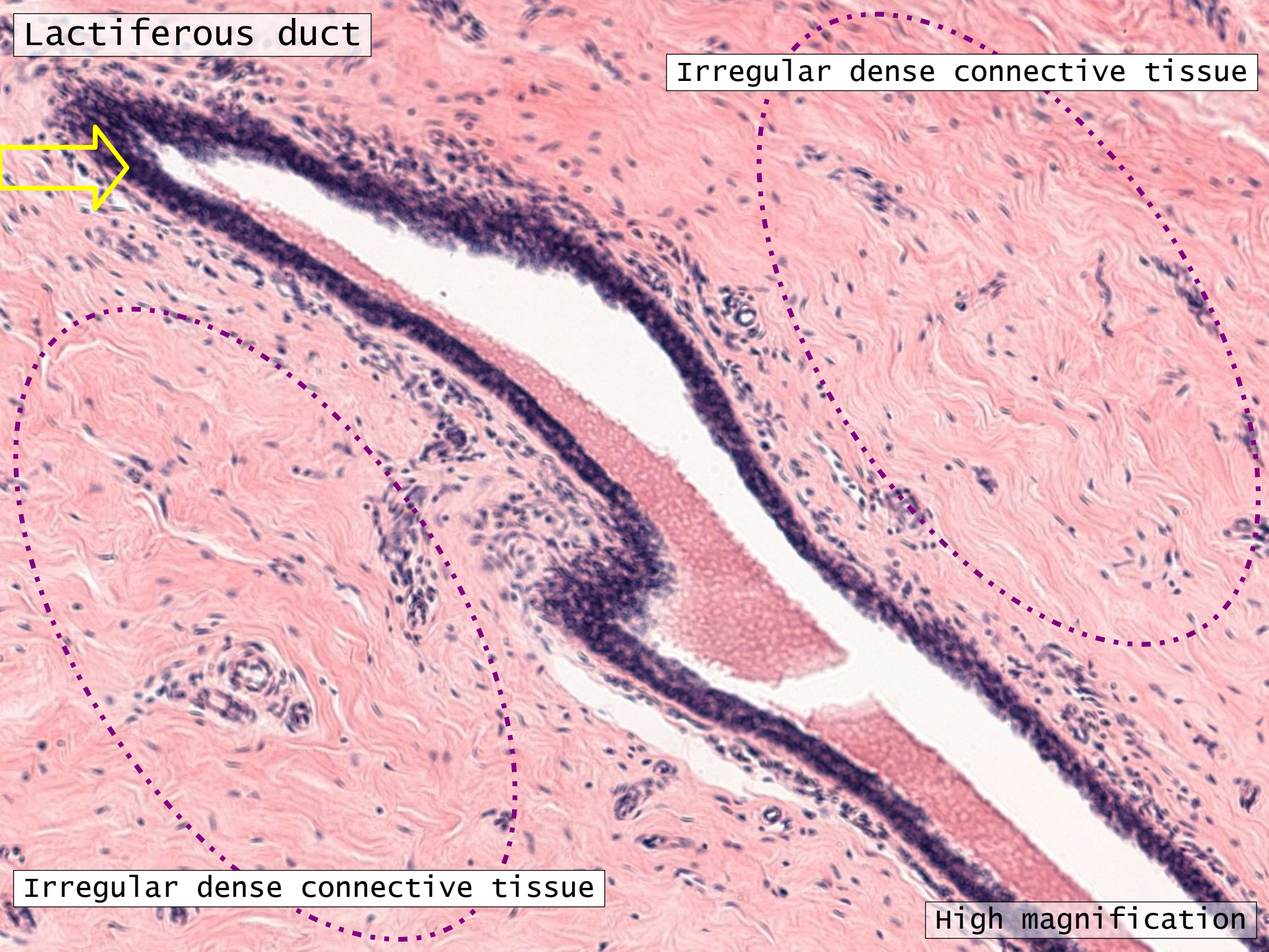
Adipose tissue

Lactiferous duct

Medium magnification

Lactiferous duct

Irregular dense connective tissue



Irregular dense connective tissue

High magnification

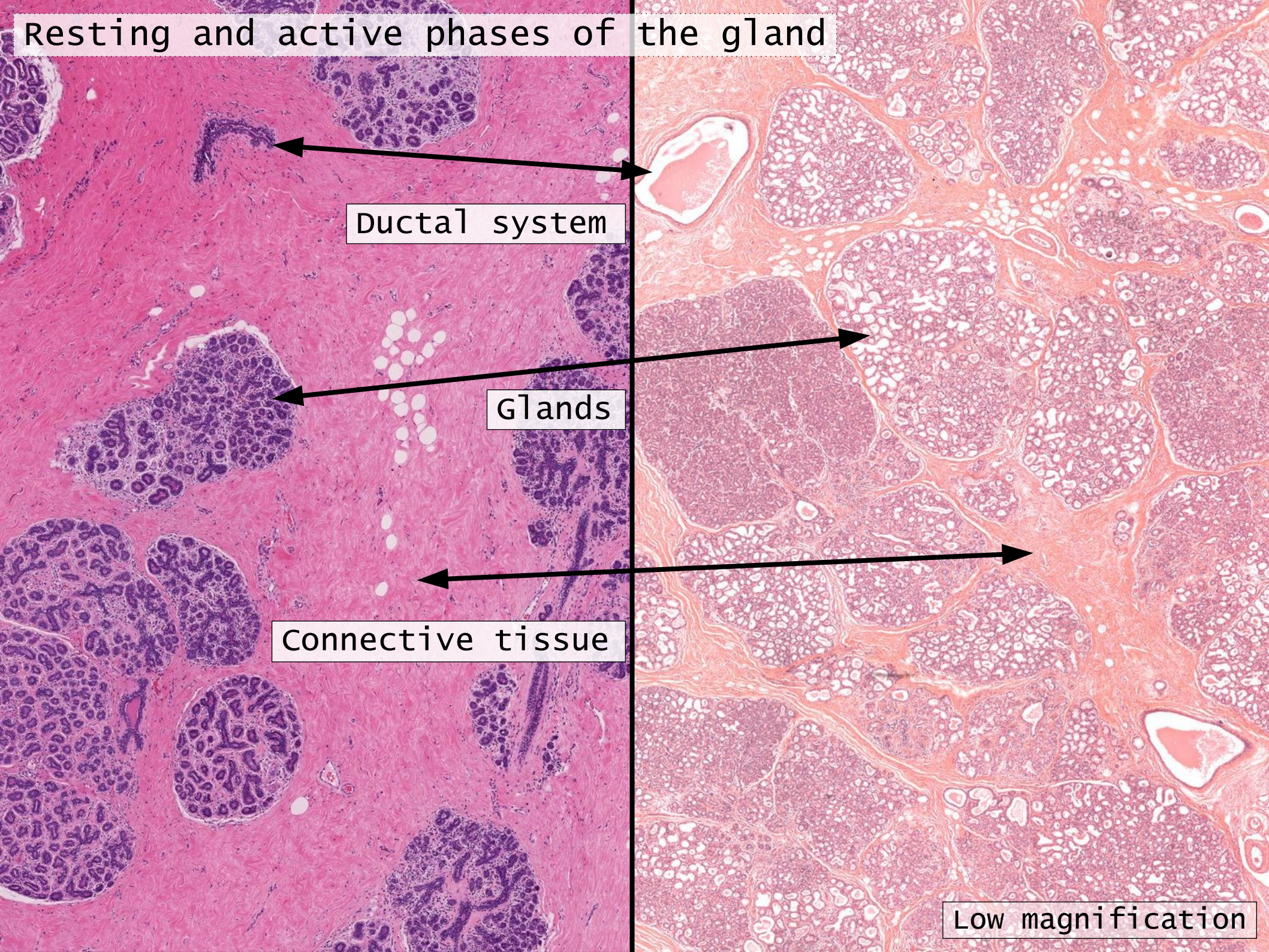
Resting and active phases of the gland

Ductal system

Glands

Connective tissue

Low magnification



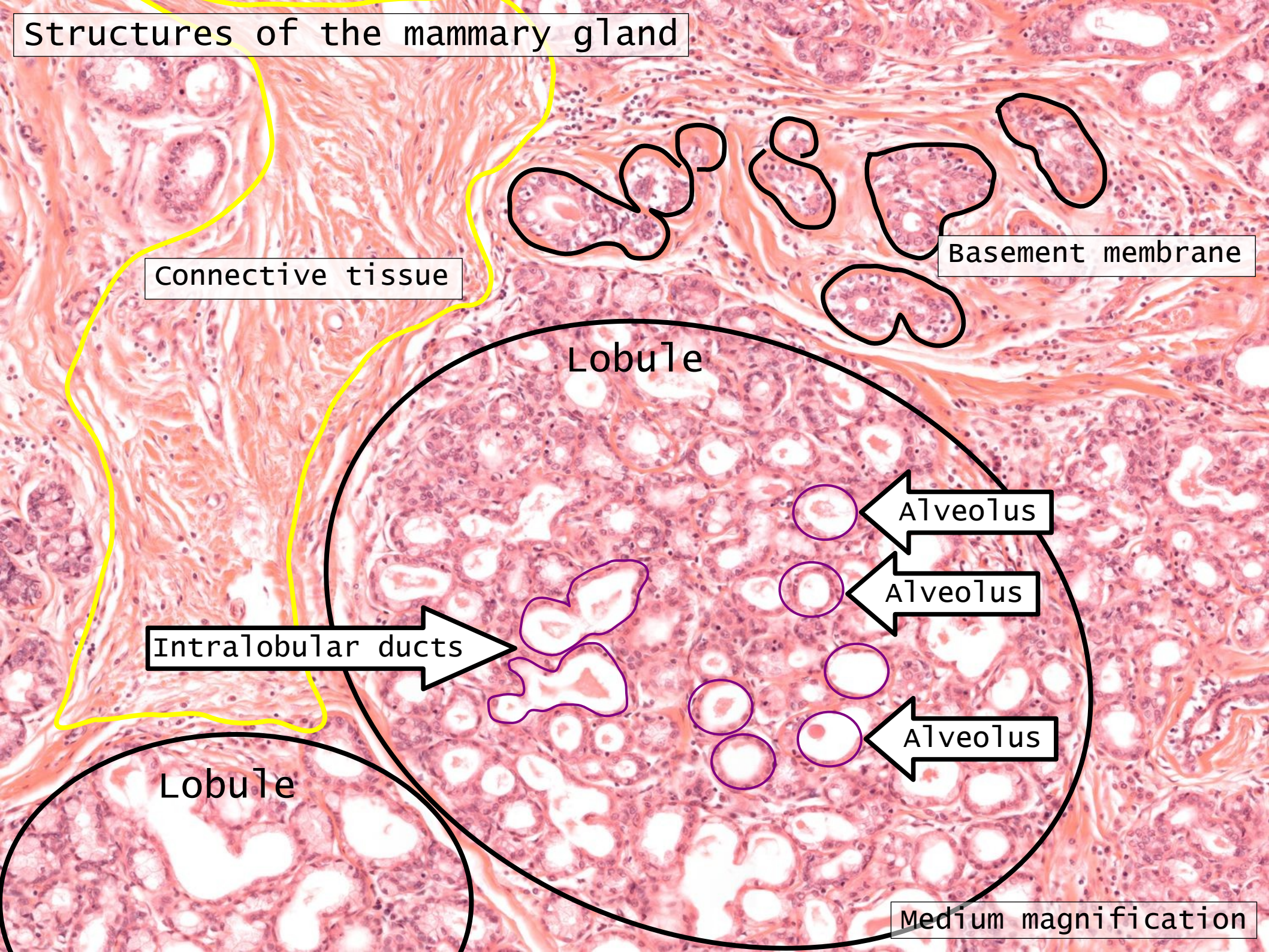
Active gland

- Much larger than resting phase
 - Terminal ducts proliferate to form alveoli
- Alveoli
 - Surrounded by incomplete myoepithelial cells

Alveolar cells

- Apocrine secretion
- Active state
- Resting state

Structures of the mammary gland



Connective tissue

Basement membrane

Lobule

Intralobular ducts

Alveolus

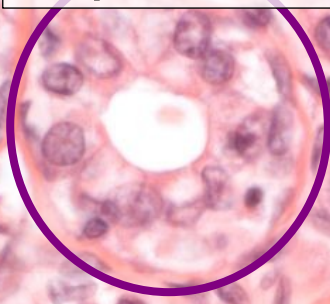Alveolus

Alveolus

Lobule


Medium magnification

Septa of the breast



Alveolus

Red blood cells in small blood vessel

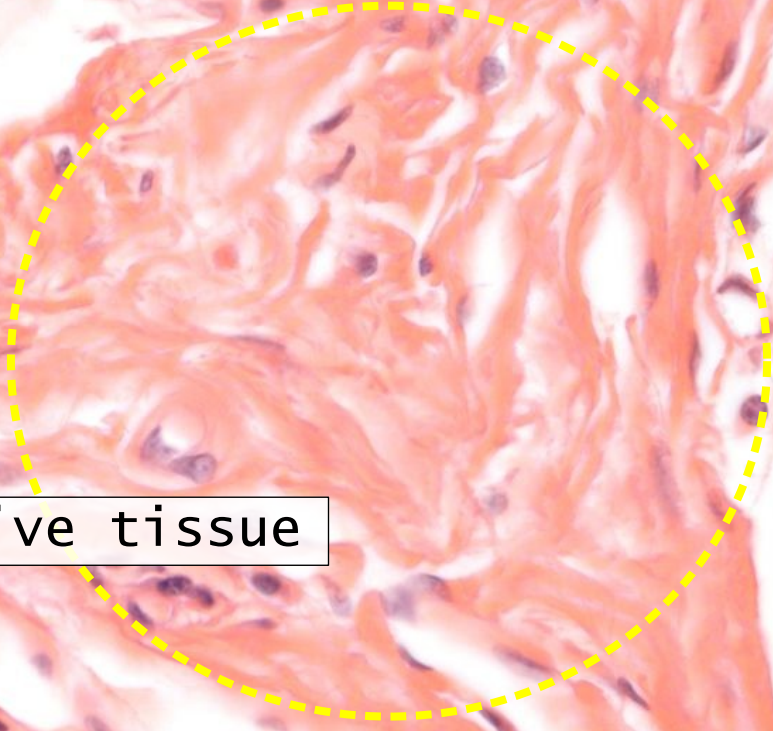

Adipose tissue

A fat cell

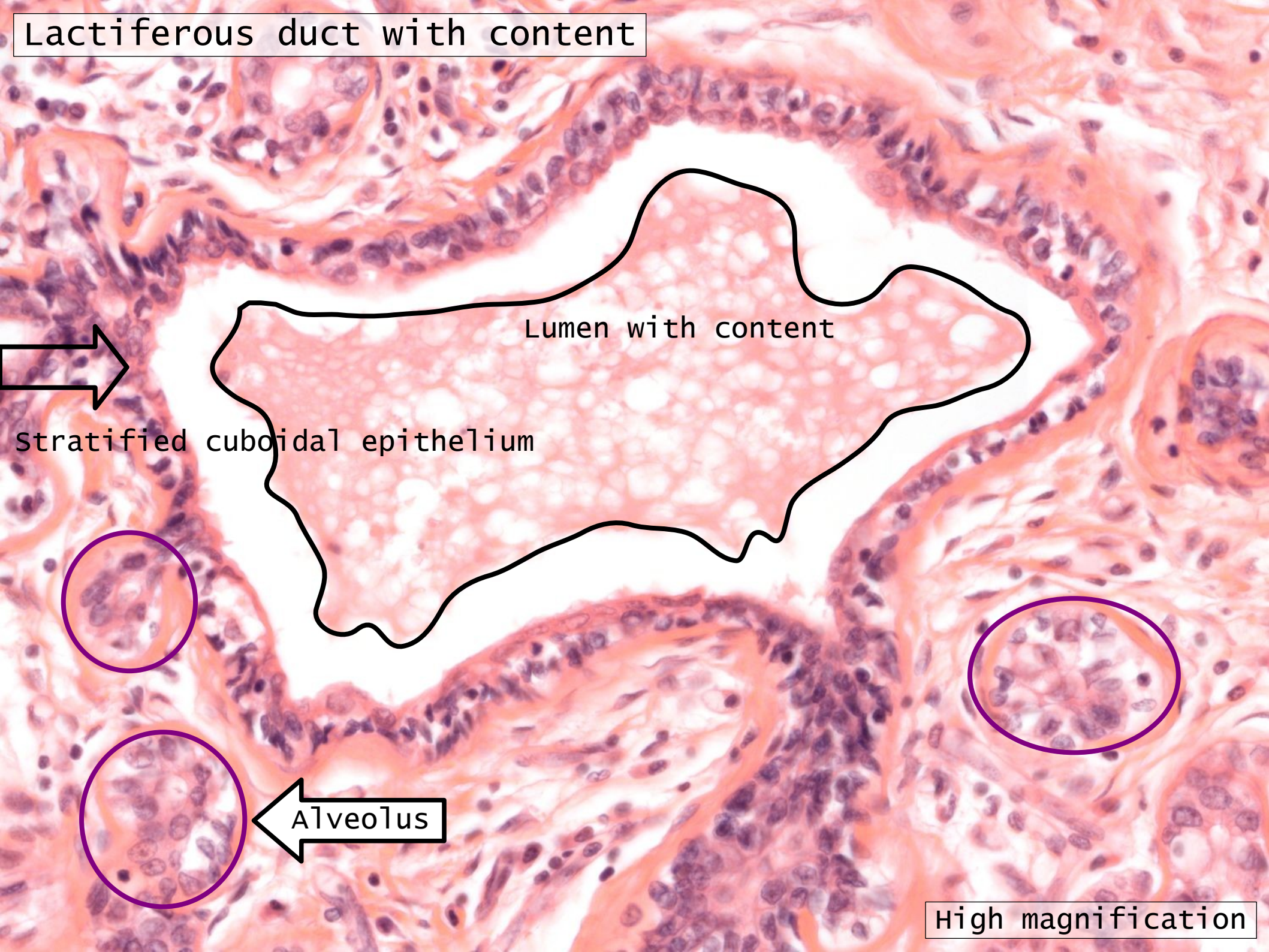


Connective tissue



High magnification

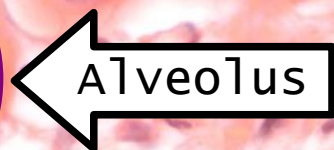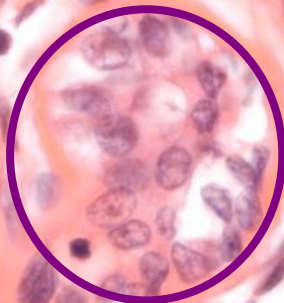
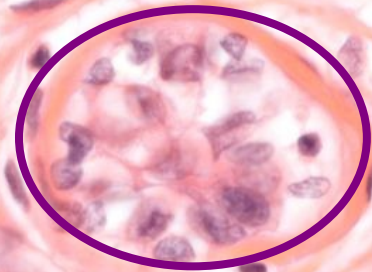
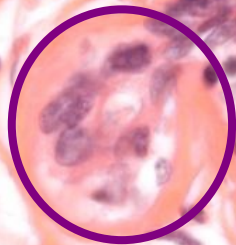
Lactiferous duct with content



Lumen with content

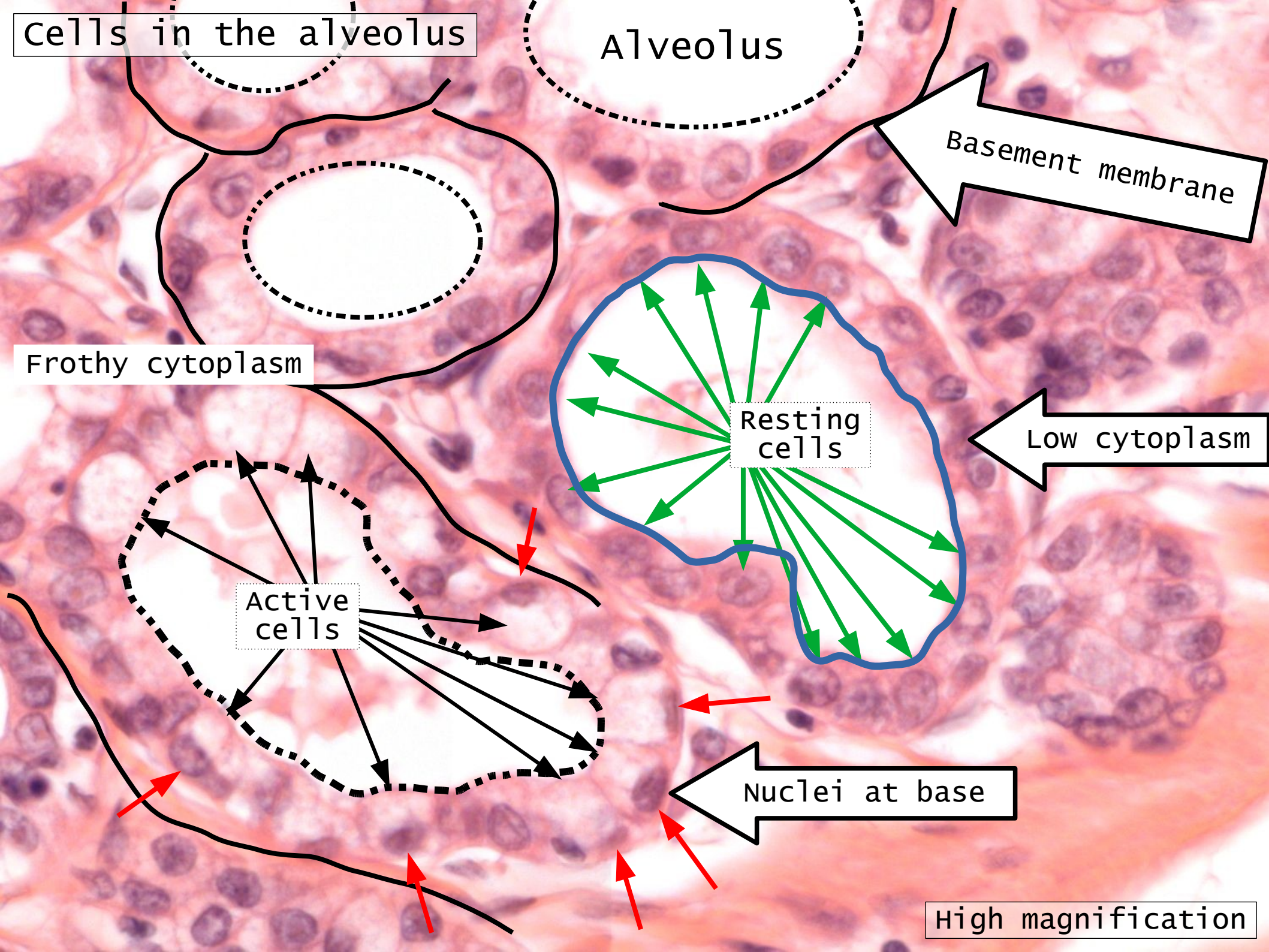


Stratified cuboidal epithelium



Alveolus

High magnification



Cells in the alveolus

Alveolus

Basement membrane

Frothy cytoplasm

Resting cells

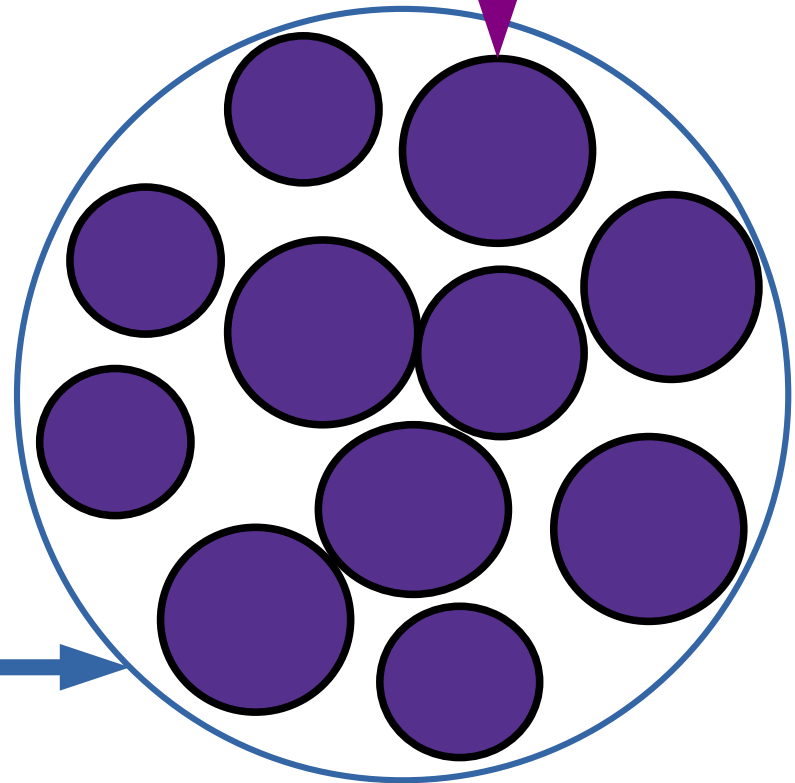
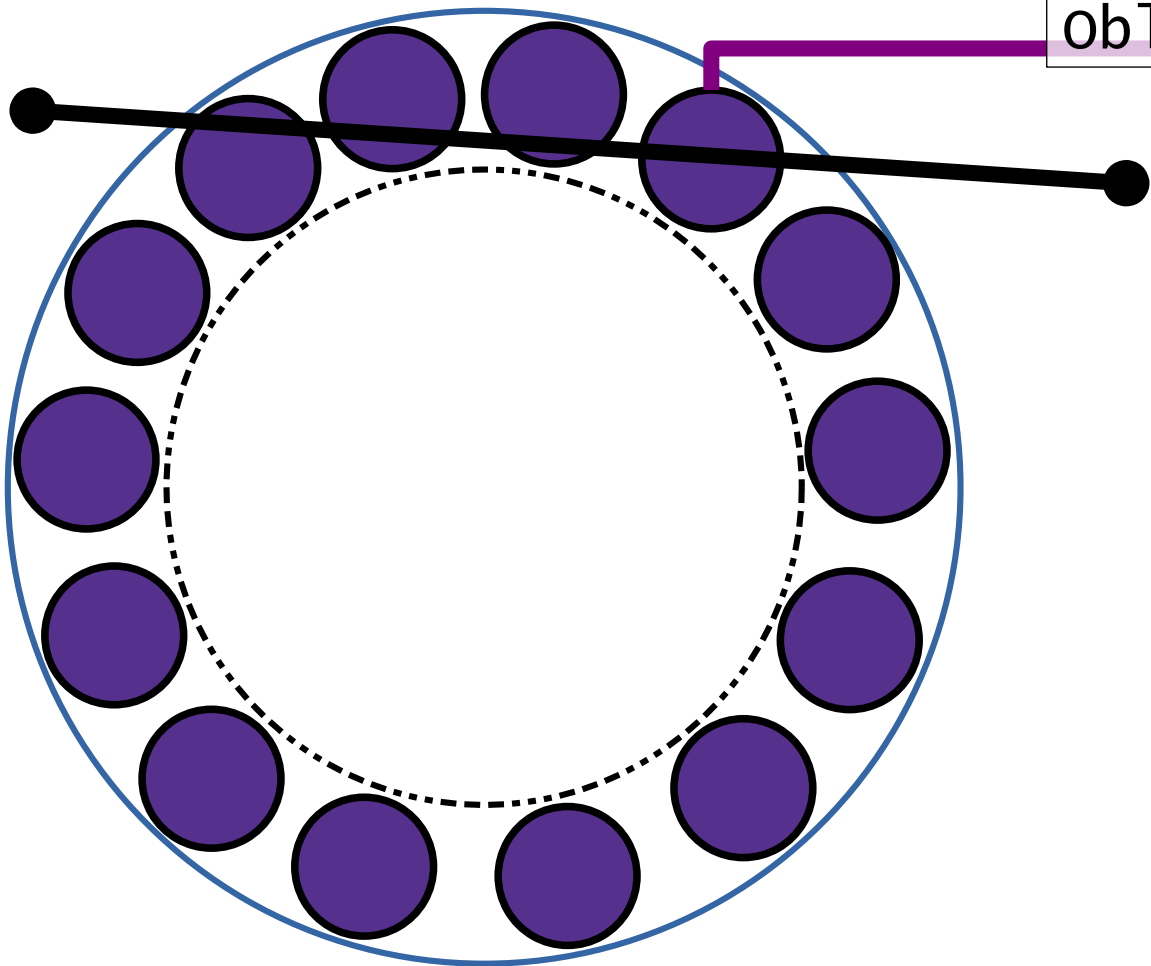
Low cytoplasm

Active cells

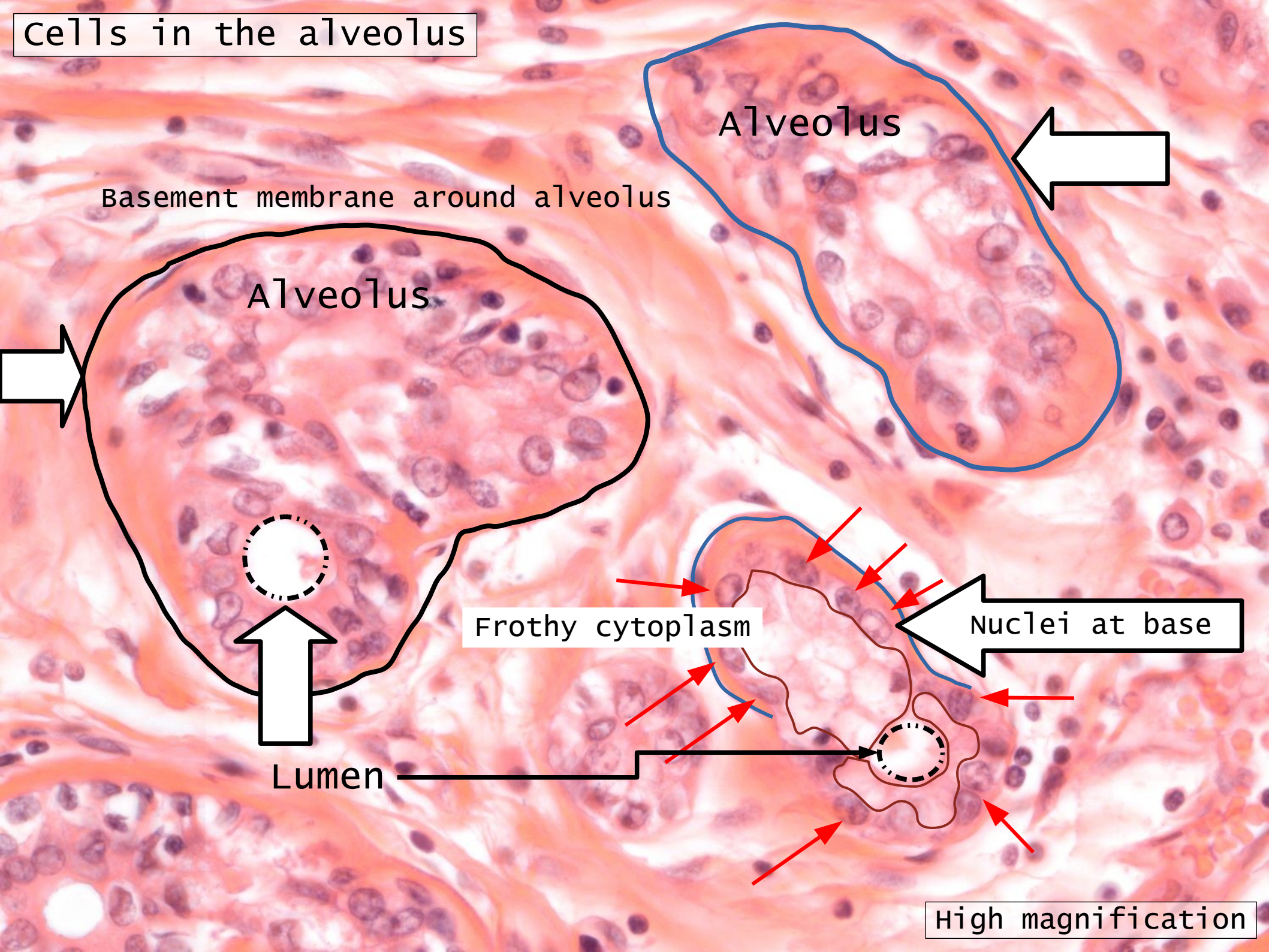
Nuclei at base

High magnification

Oblique cut through alveolus



Cells in the alveolus



Alveolus

Basement membrane around alveolus

Alveolus

Frothy cytoplasm

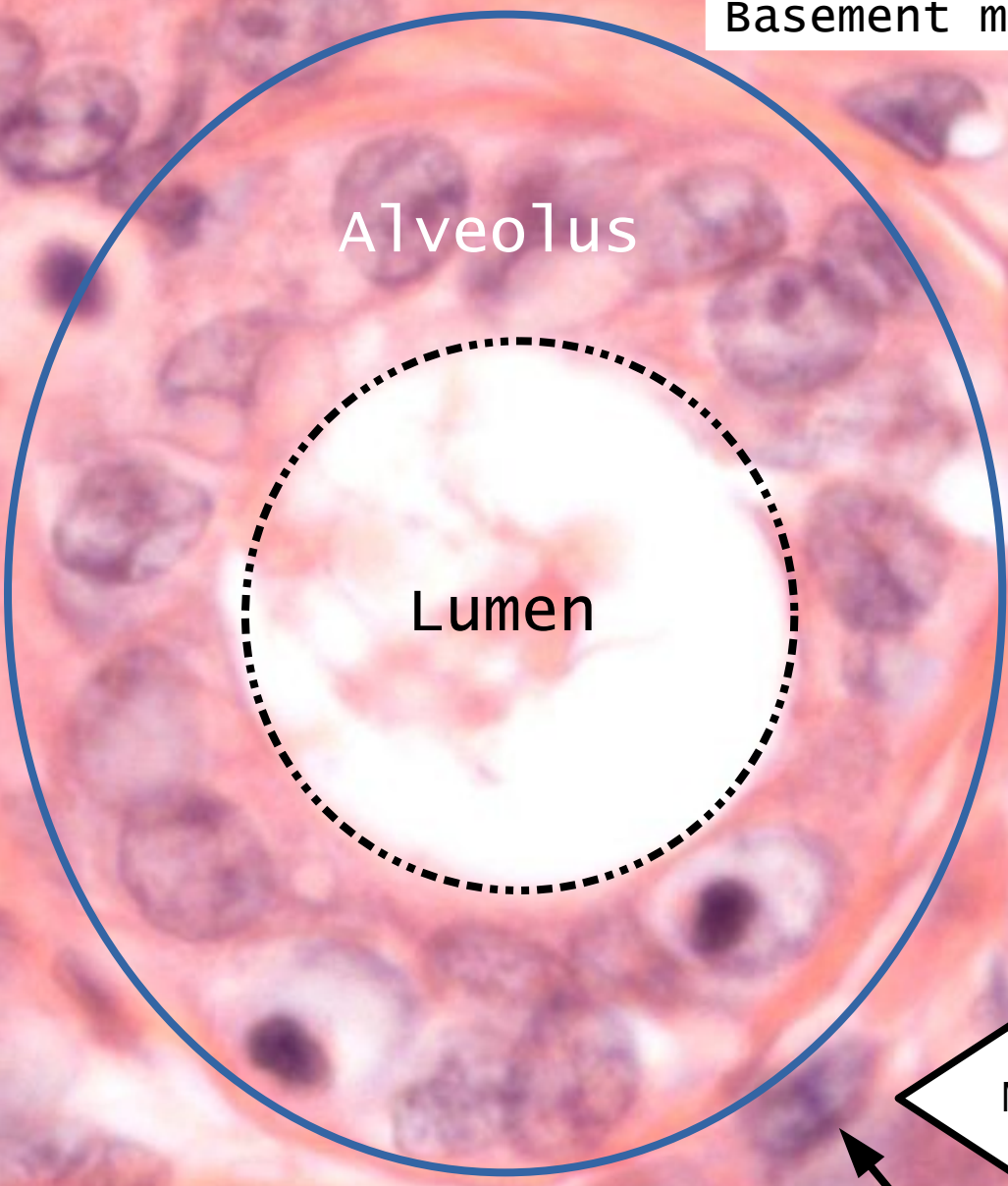
Nuclei at base

Lumen

High magnification

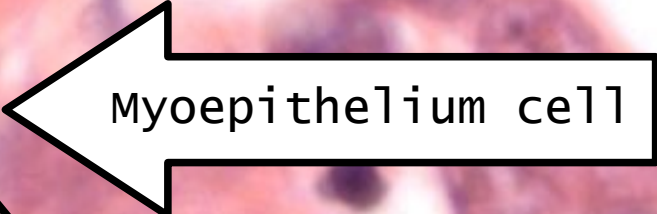
Detail of alveolus - myoepithelium

Basement membrane around alveolus



Alveolus

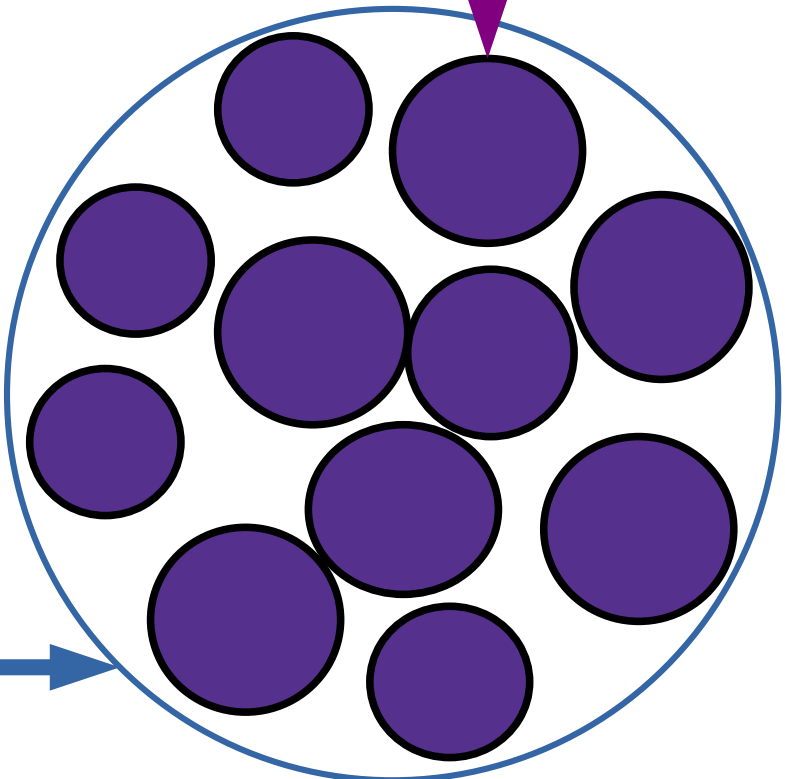
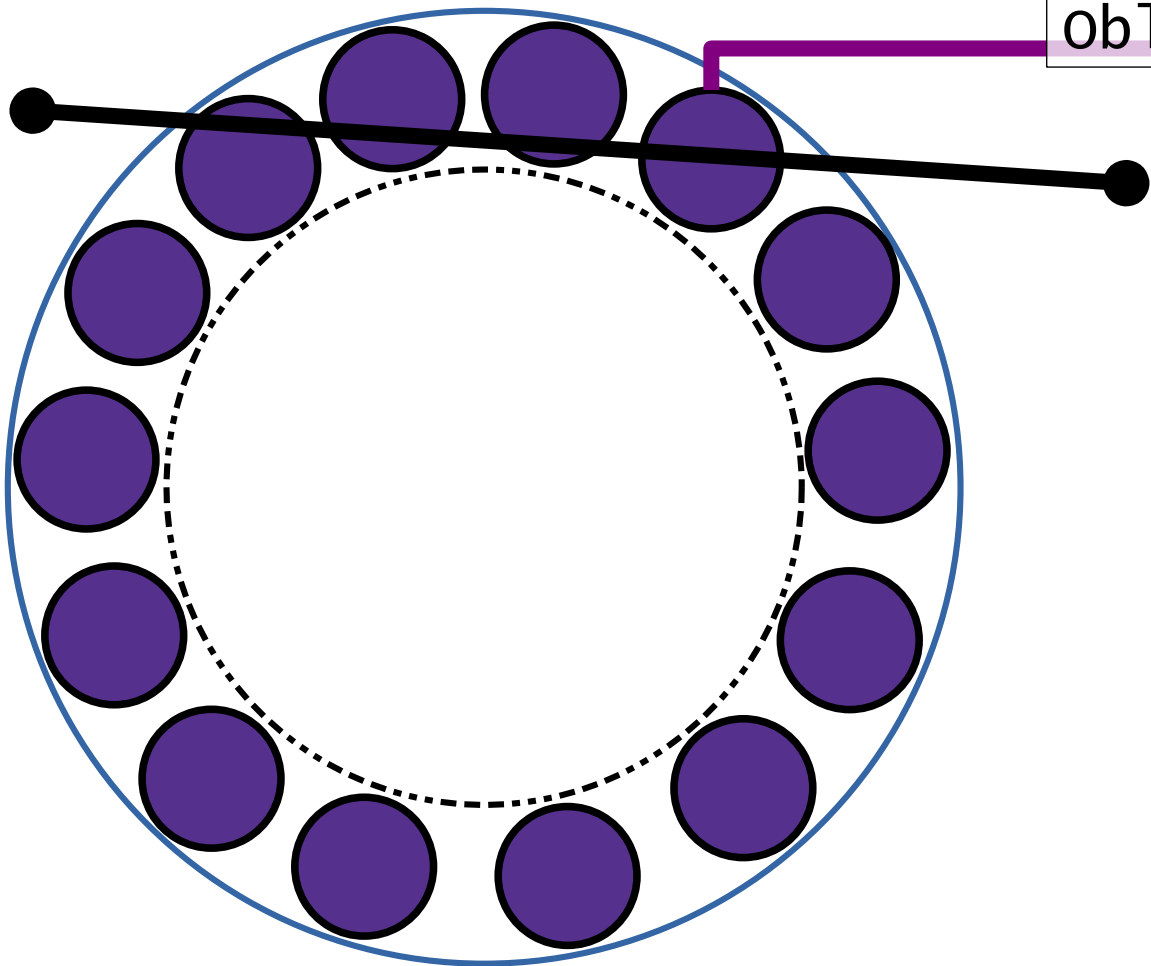
Lumen



Myoepithelium cell

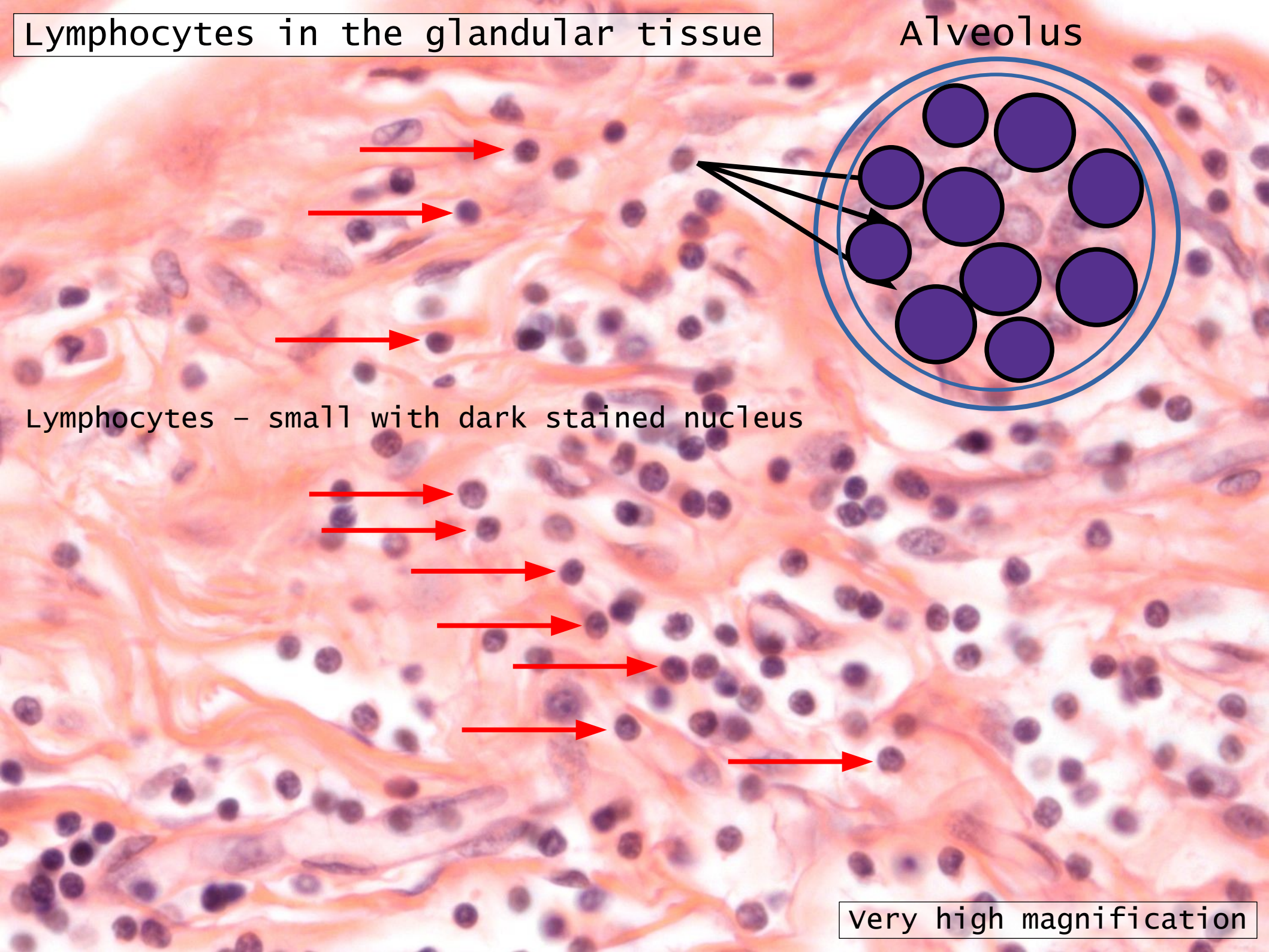
very high magnification

Oblique cut through alveolus



Lymphocytes in the glandular tissue

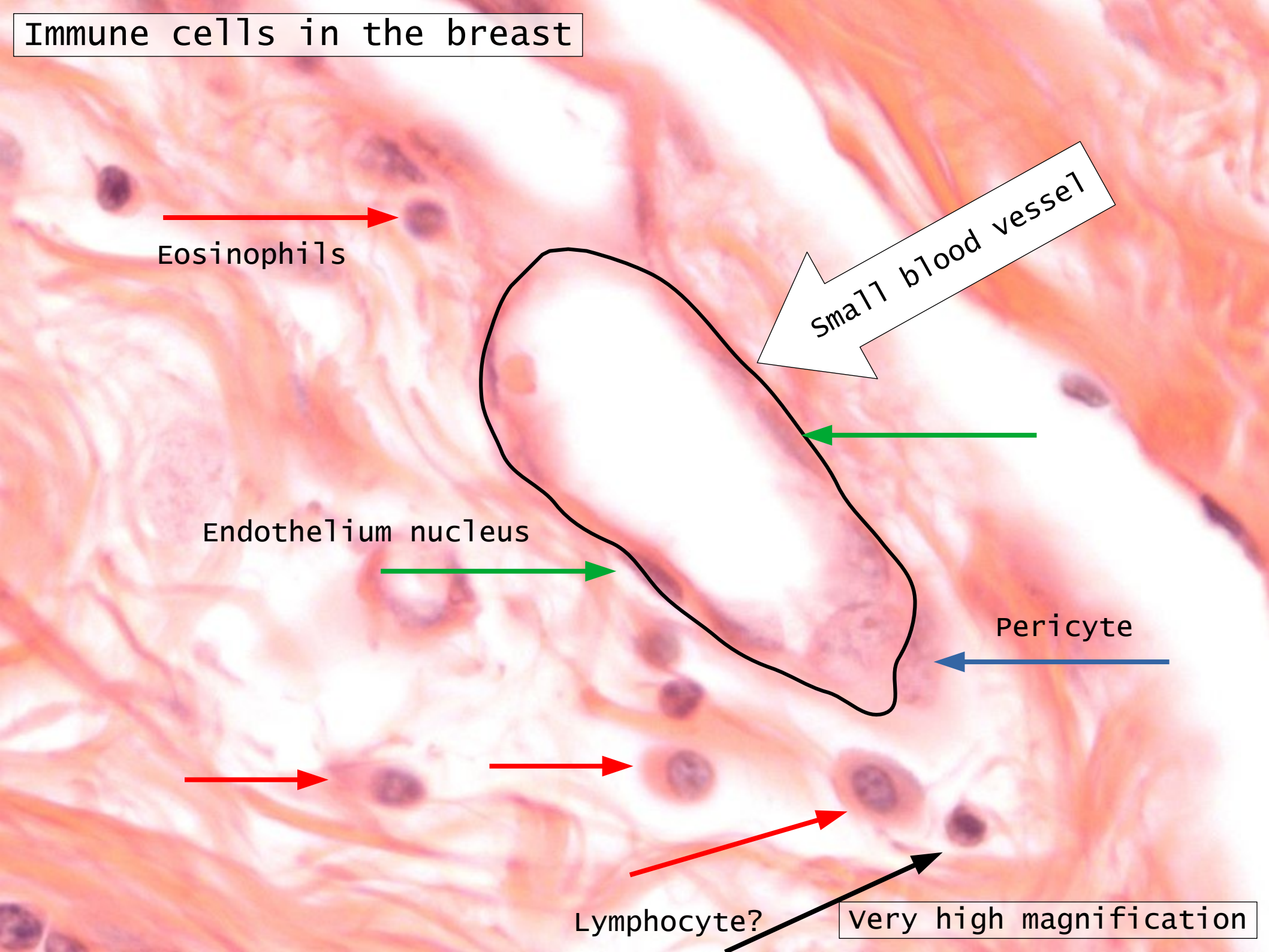
Alveolus



Lymphocytes - small with dark stained nucleus

very high magnification

Immune cells in the breast



Eosinophils

Small blood vessel

Endothelium nucleus

Pericyte

Lymphocyte?

very high magnification

Basement membrane?

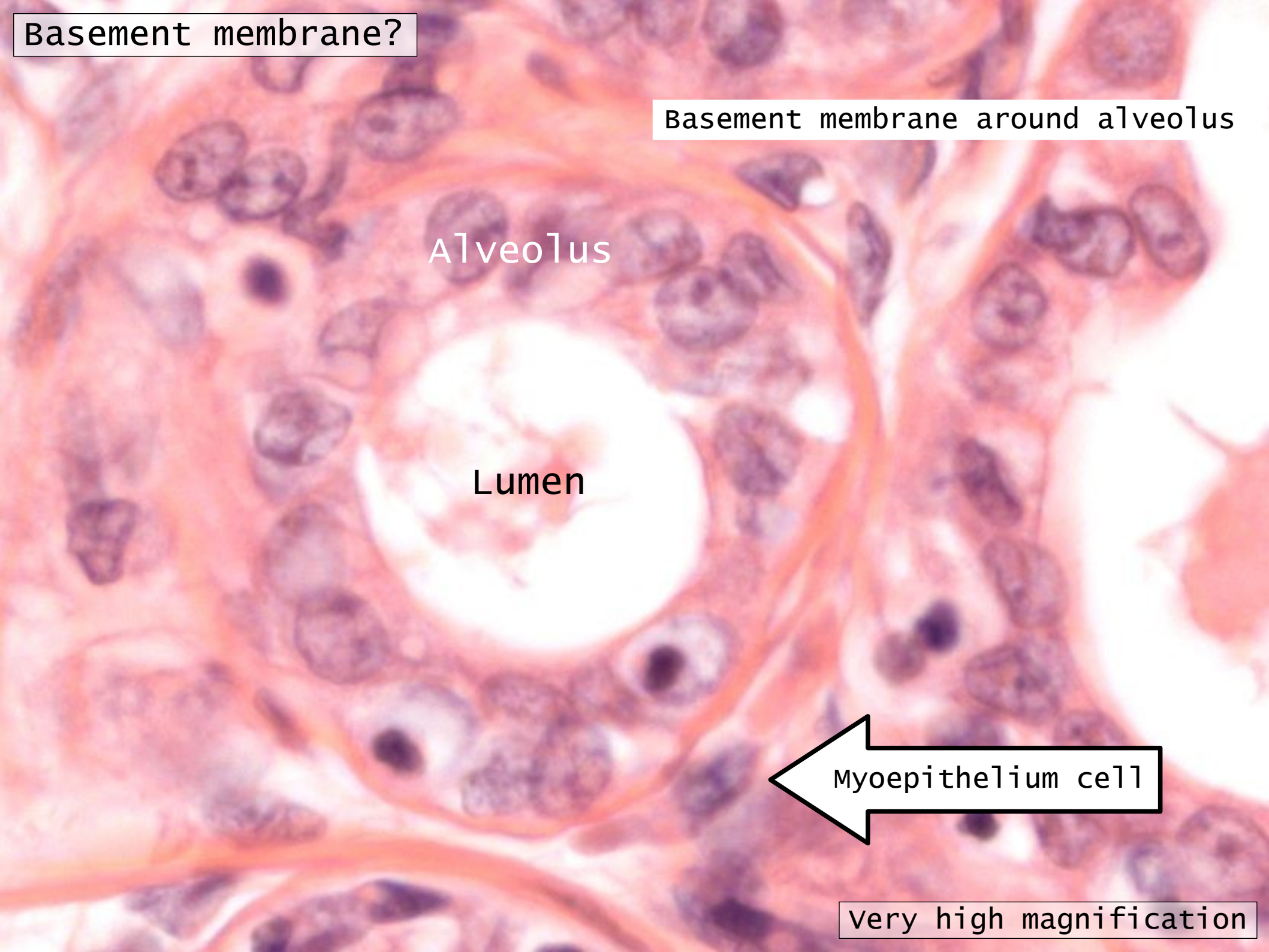
Basement membrane around alveolus

Alveolus

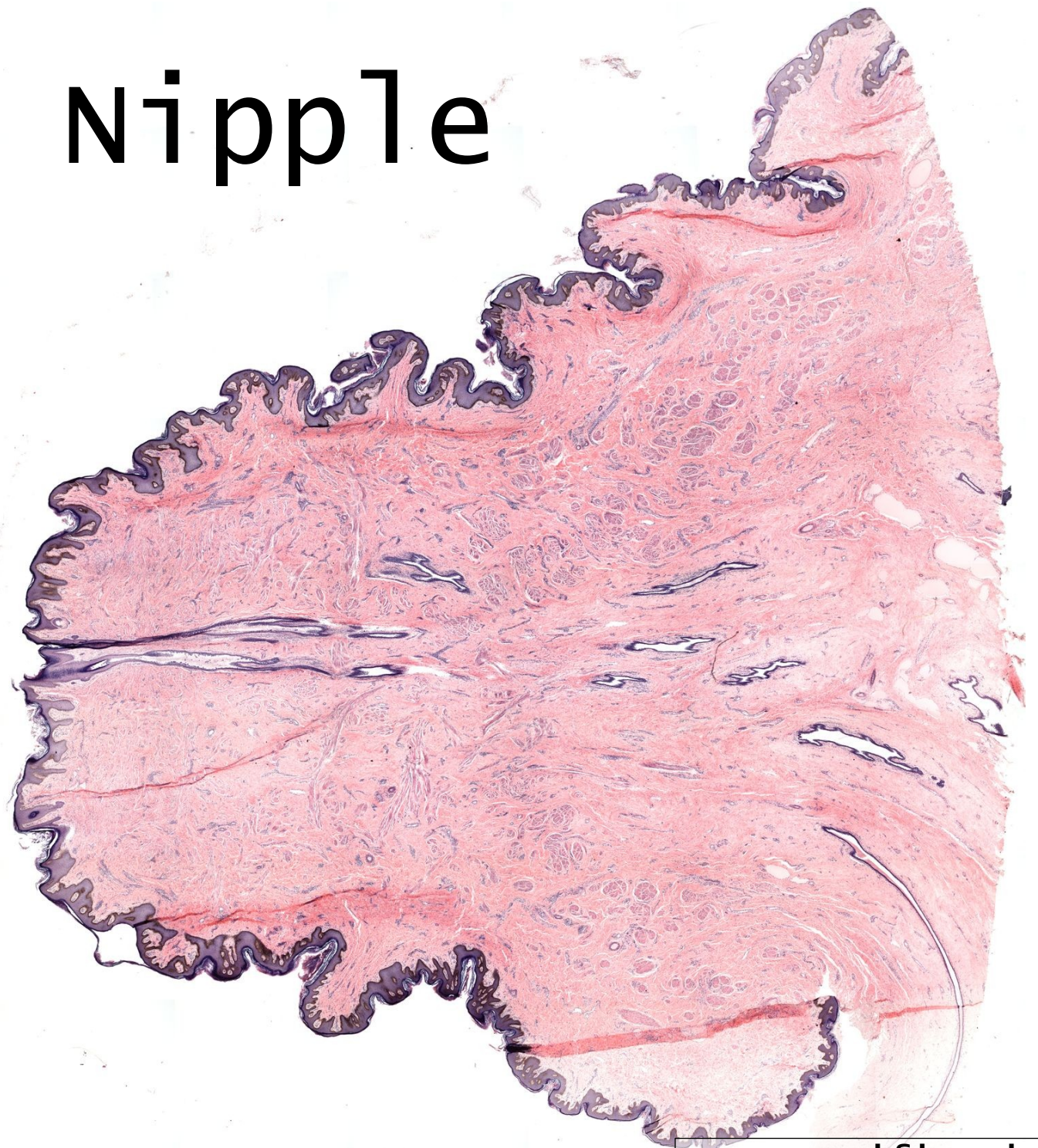
Lumen

Myoepithelium cell

very high magnification



Nipple




Low magnification

Morphology

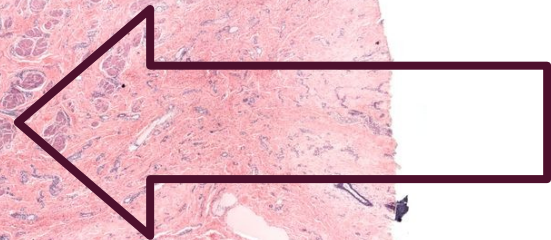
- Covered with skin
- Consists of dense collagenous connective tissue
- Interlaced with smooth muscle fibres
- Contains openings of lactiferous ducts

Structures in the nipple

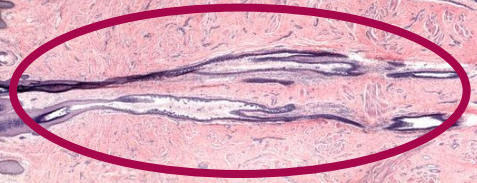
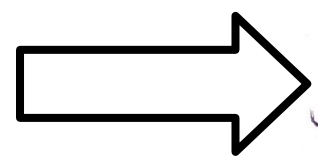
Keratinized stratified squamous epithelium



Smooth muscle bundles



Opening on skin

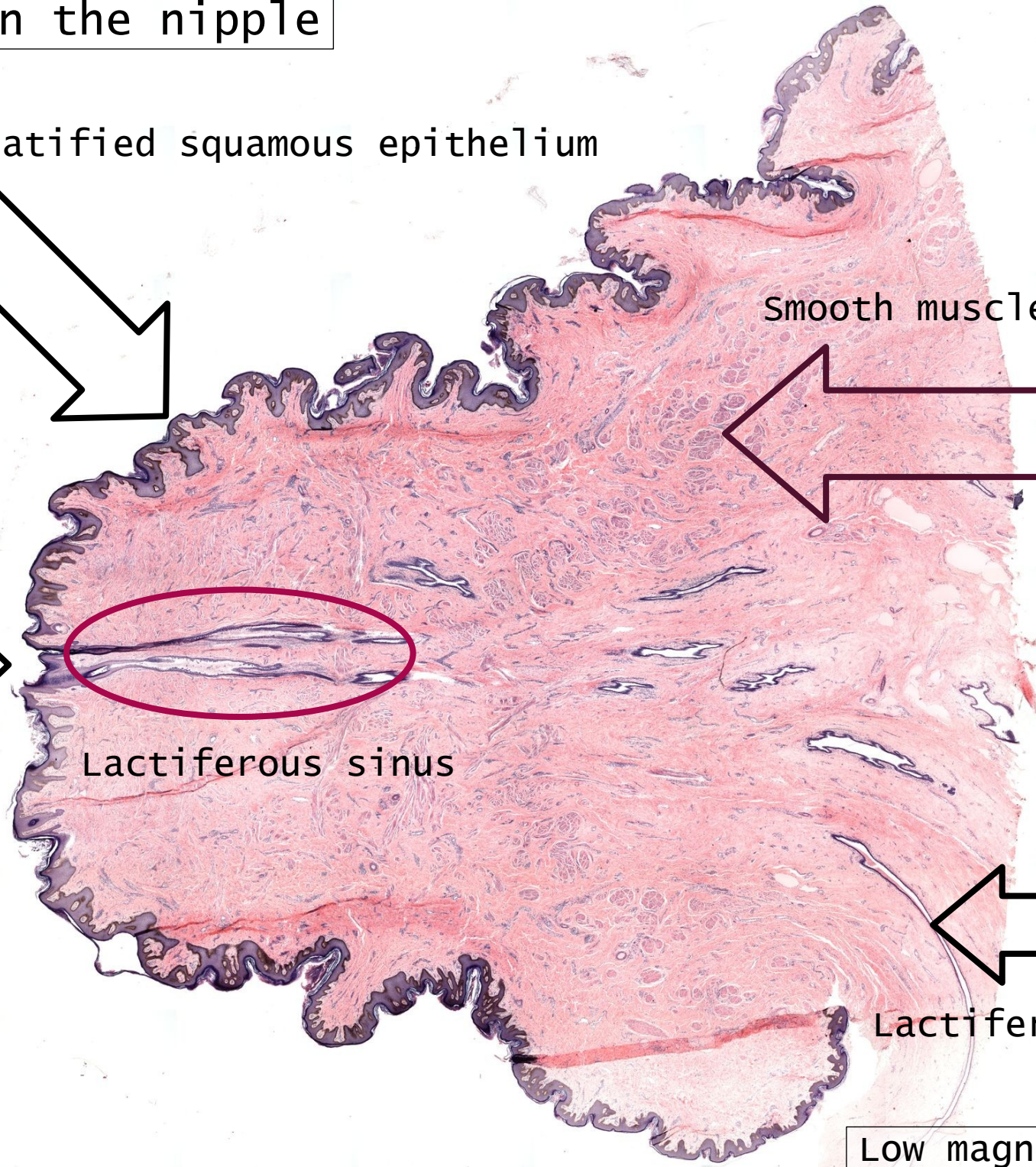


Lactiferous sinus

Lactiferous duct



Low magnification



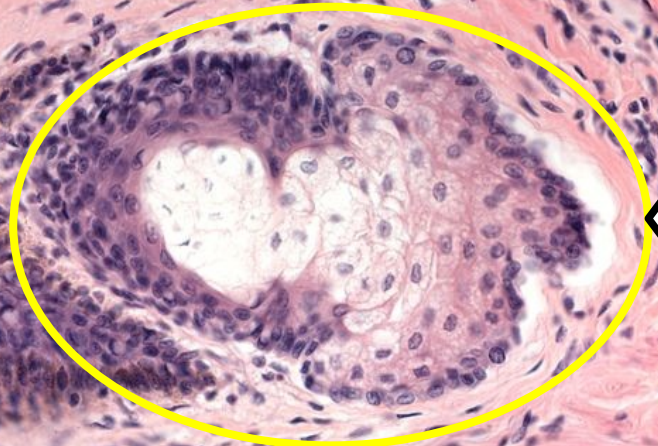
skin

- Keratinized stratified squamous epithelium
- Sebaceous glands


Opening of the lactiferous sinus



Keratinized stratified squamous epithelium

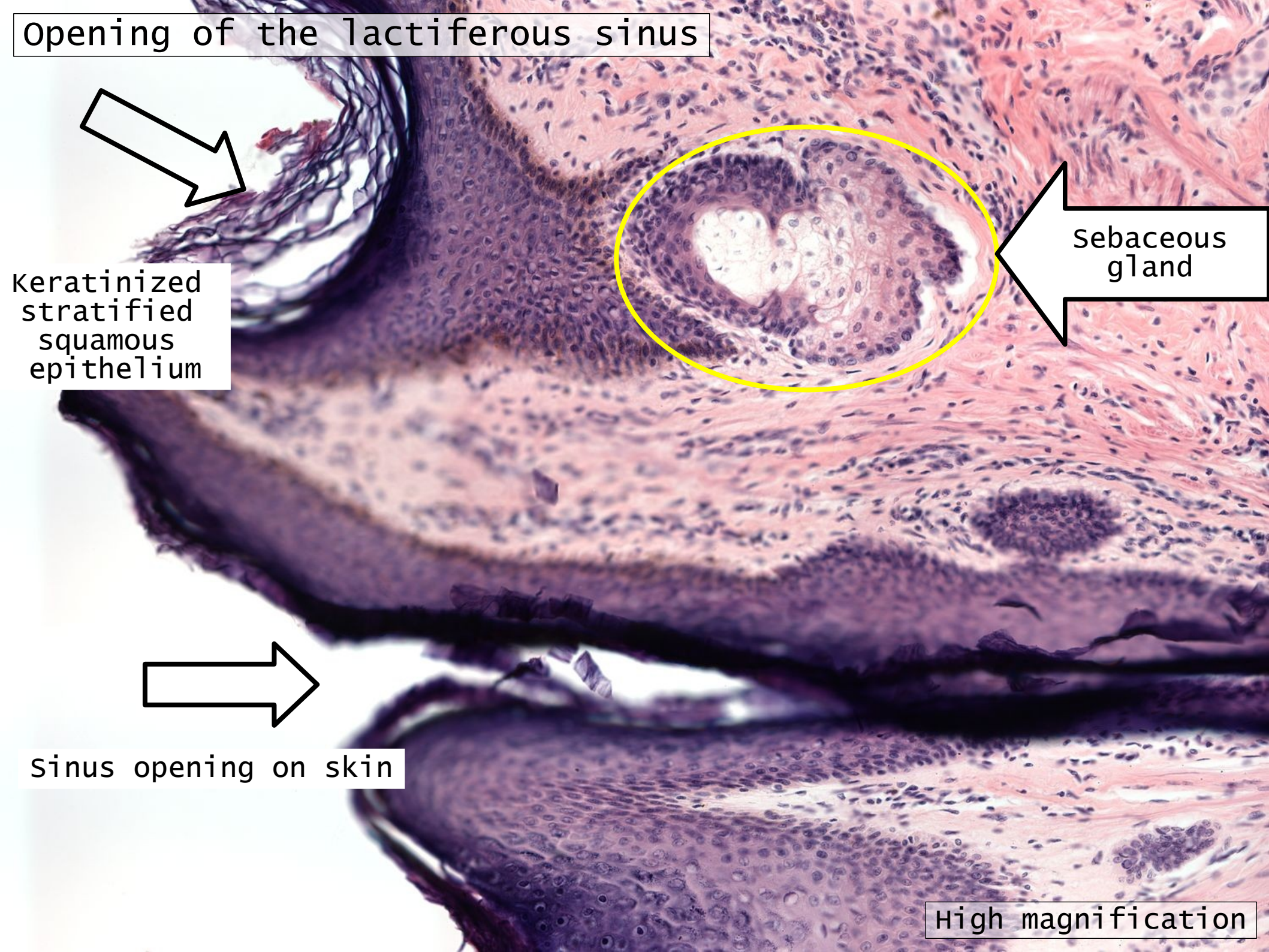


Sebaceous gland



Sinus opening on skin

High magnification



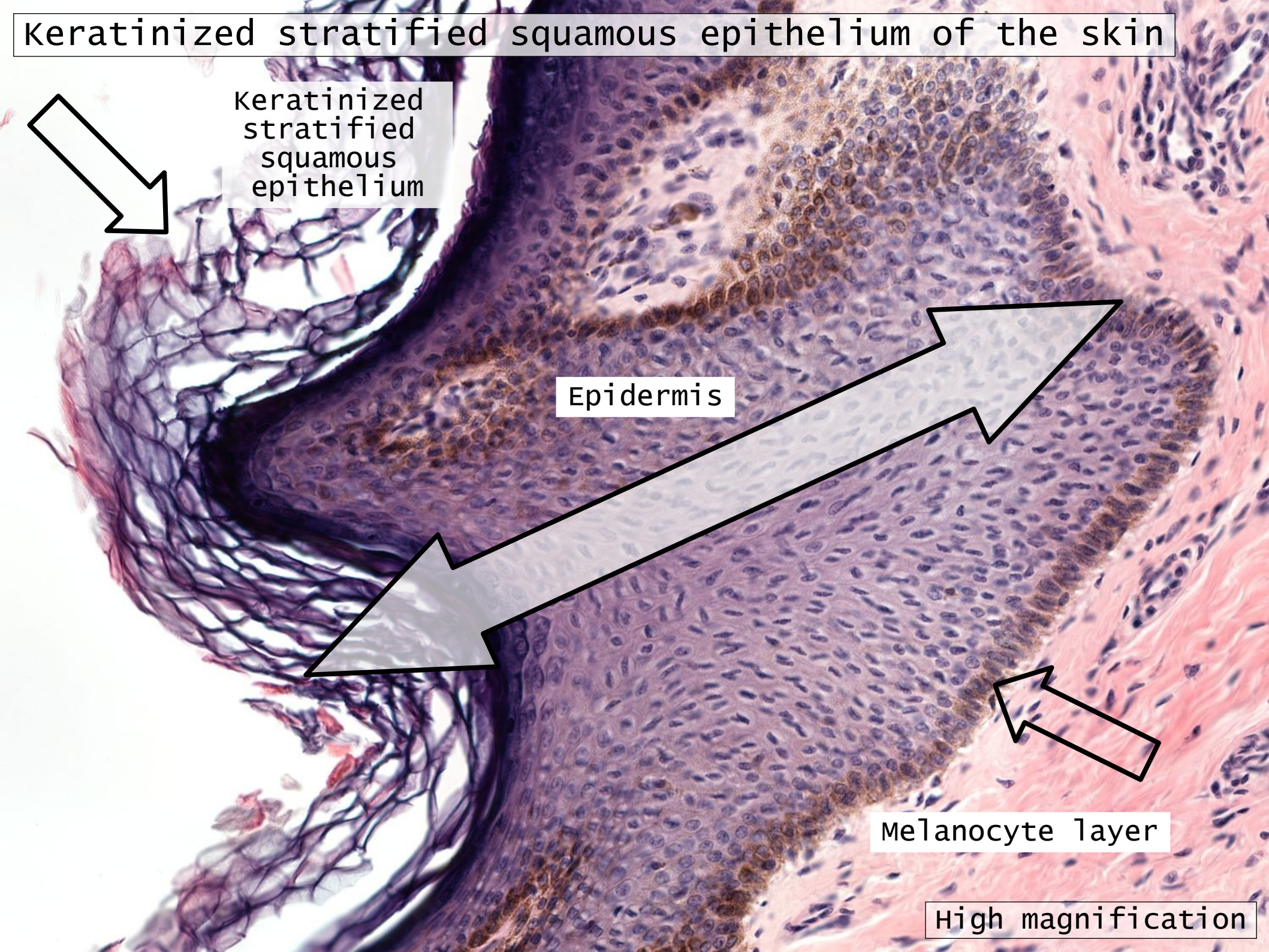
Keratinized stratified squamous epithelium of the skin

Keratinized stratified squamous epithelium

Epidermis

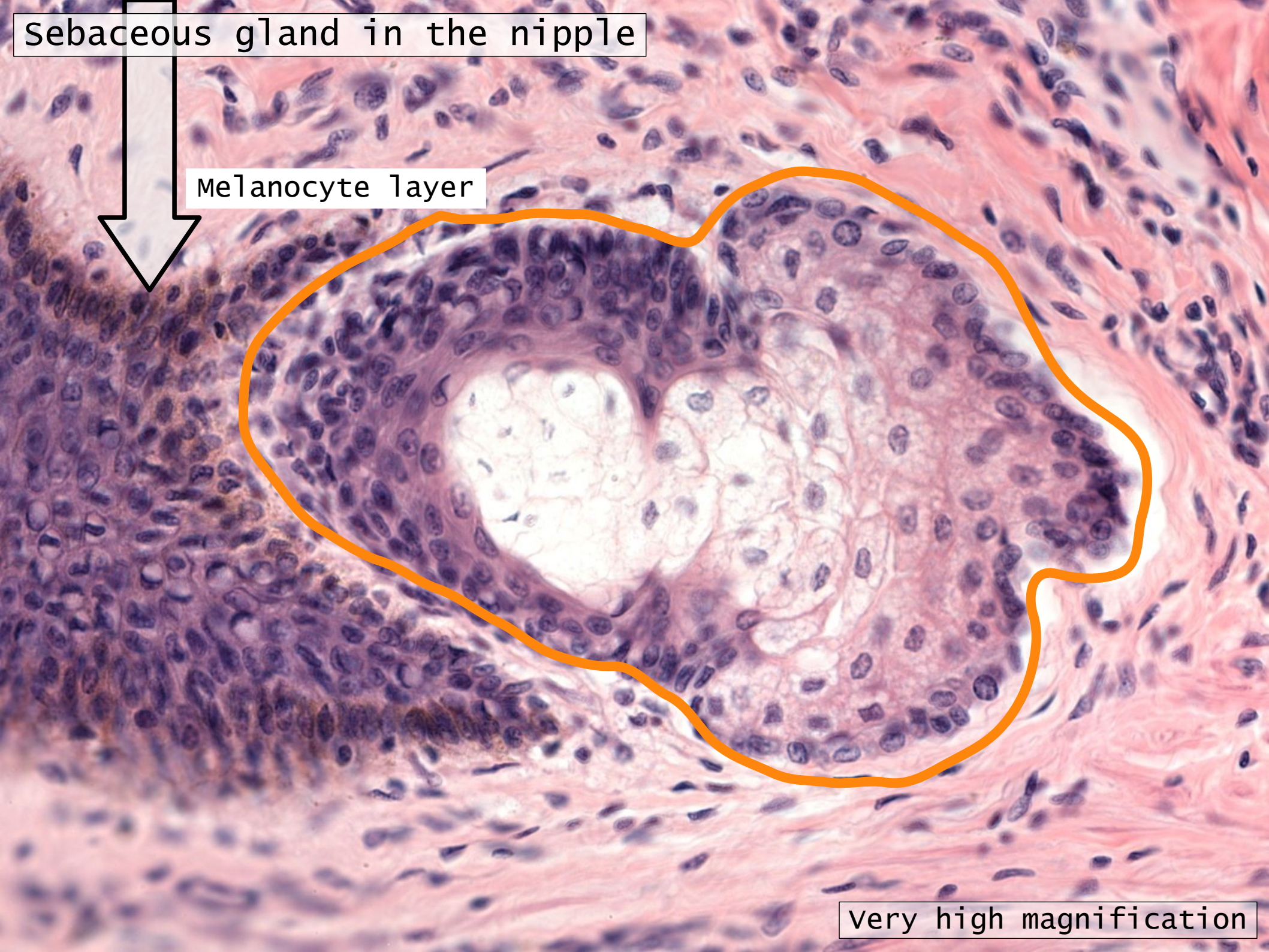
Melanocyte layer

High magnification

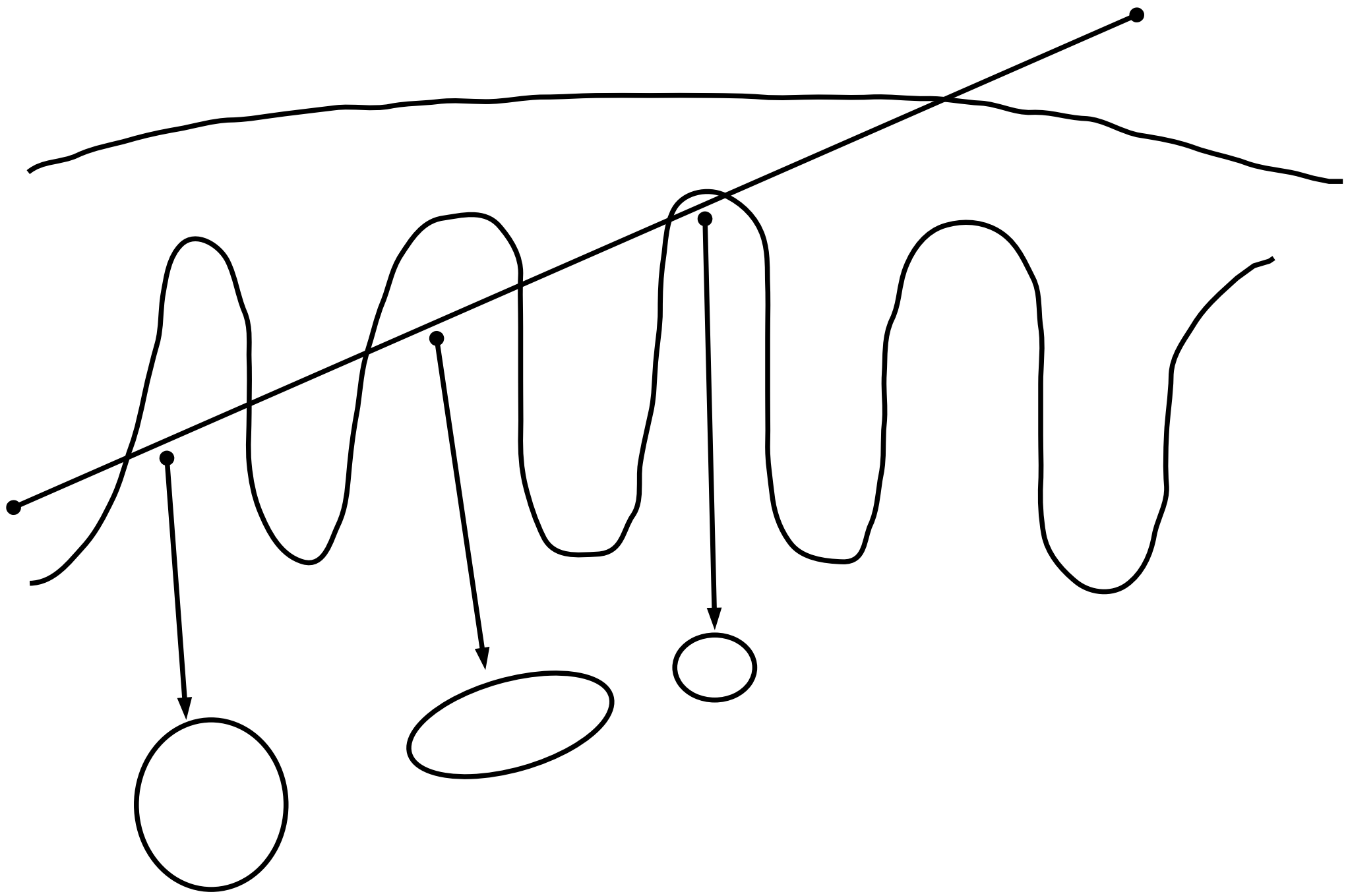


Sebaceous gland in the nipple

Melanocyte layer



very high magnification



Papillary layer of skin

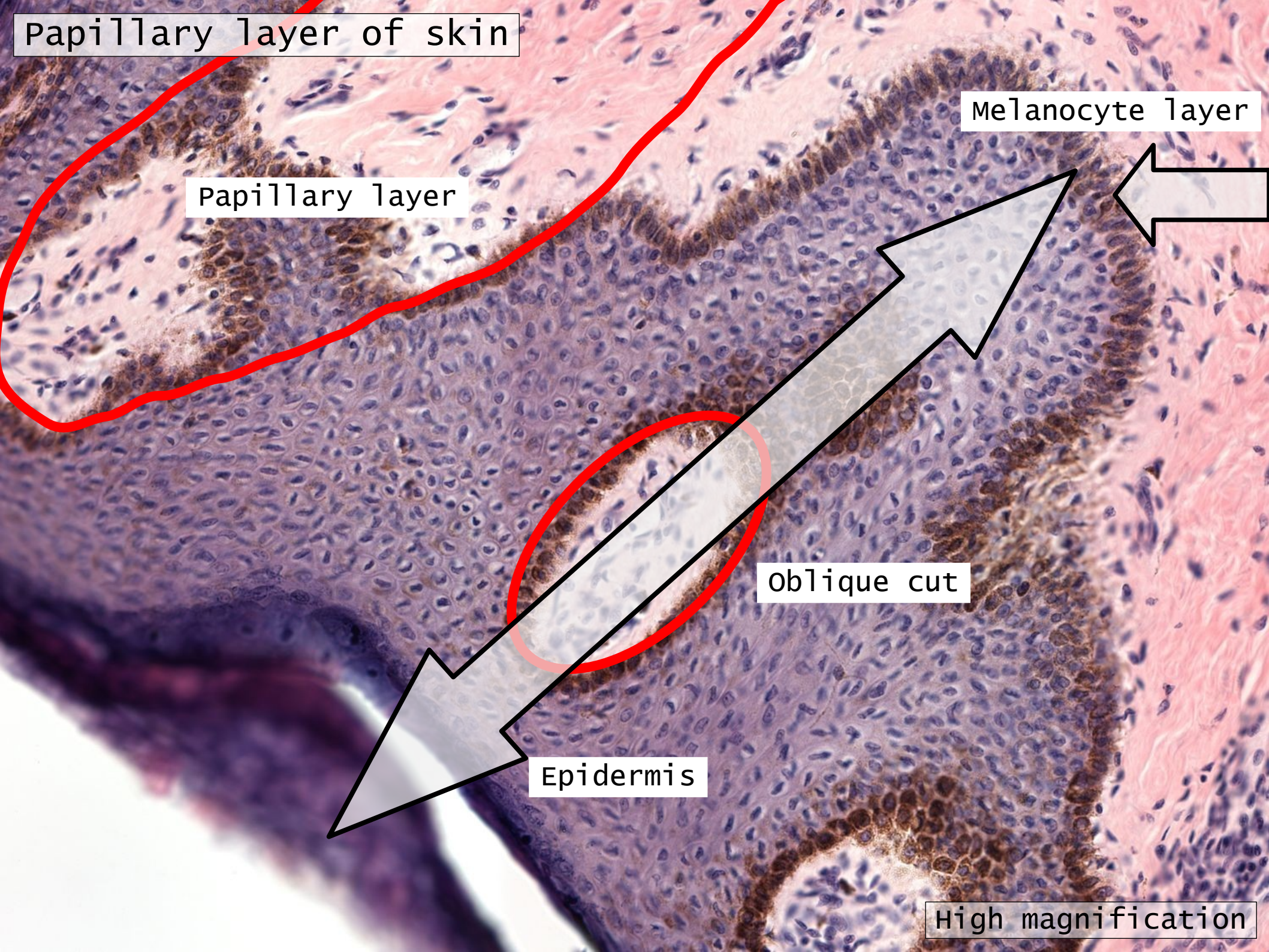
Melanocyte layer

Papillary layer

Oblique cut

Epidermis

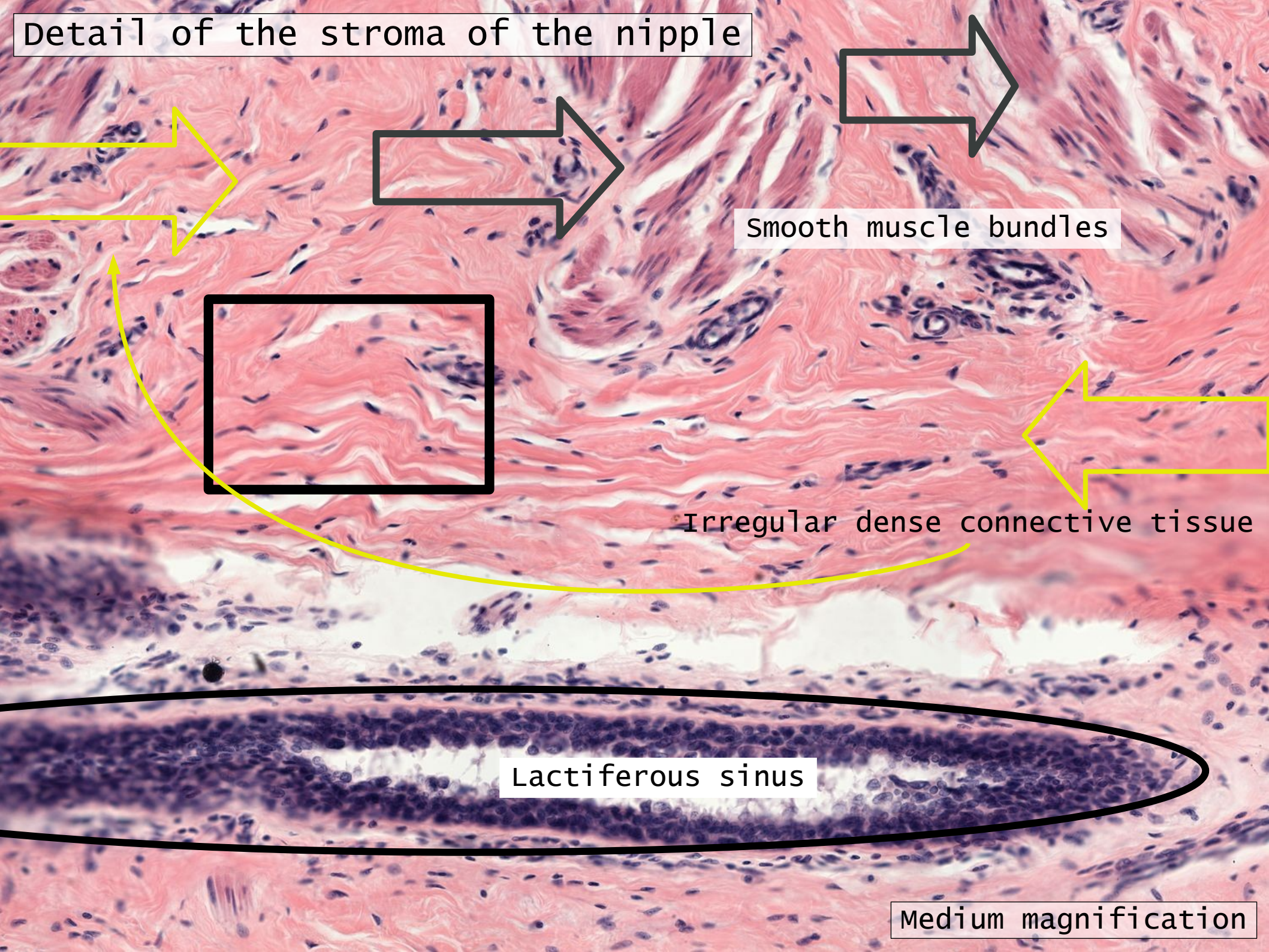
High magnification



Stroma

- collagenous connective tissue
 - Irregular dense connective tissue
- Smooth muscle
 - Fibres and bundles
- Lactiferous sinusses
 - Stratified cuboidal epithelium

Detail of the stroma of the nipple



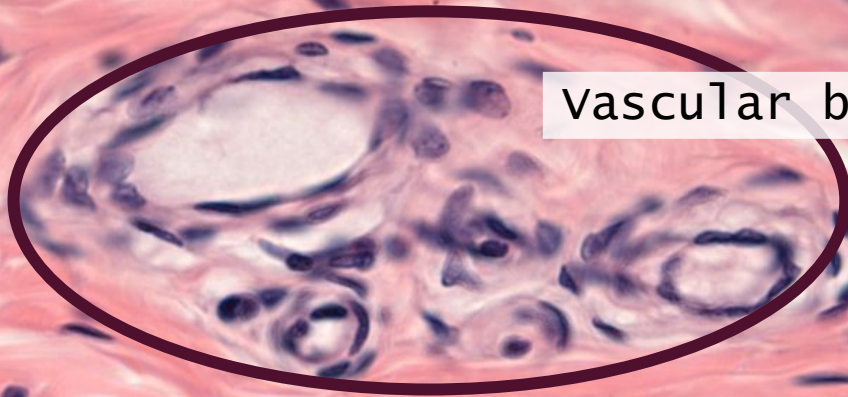
Smooth muscle bundles

Irregular dense connective tissue

Lactiferous sinus

Medium magnification

Irregular dense connective tissue



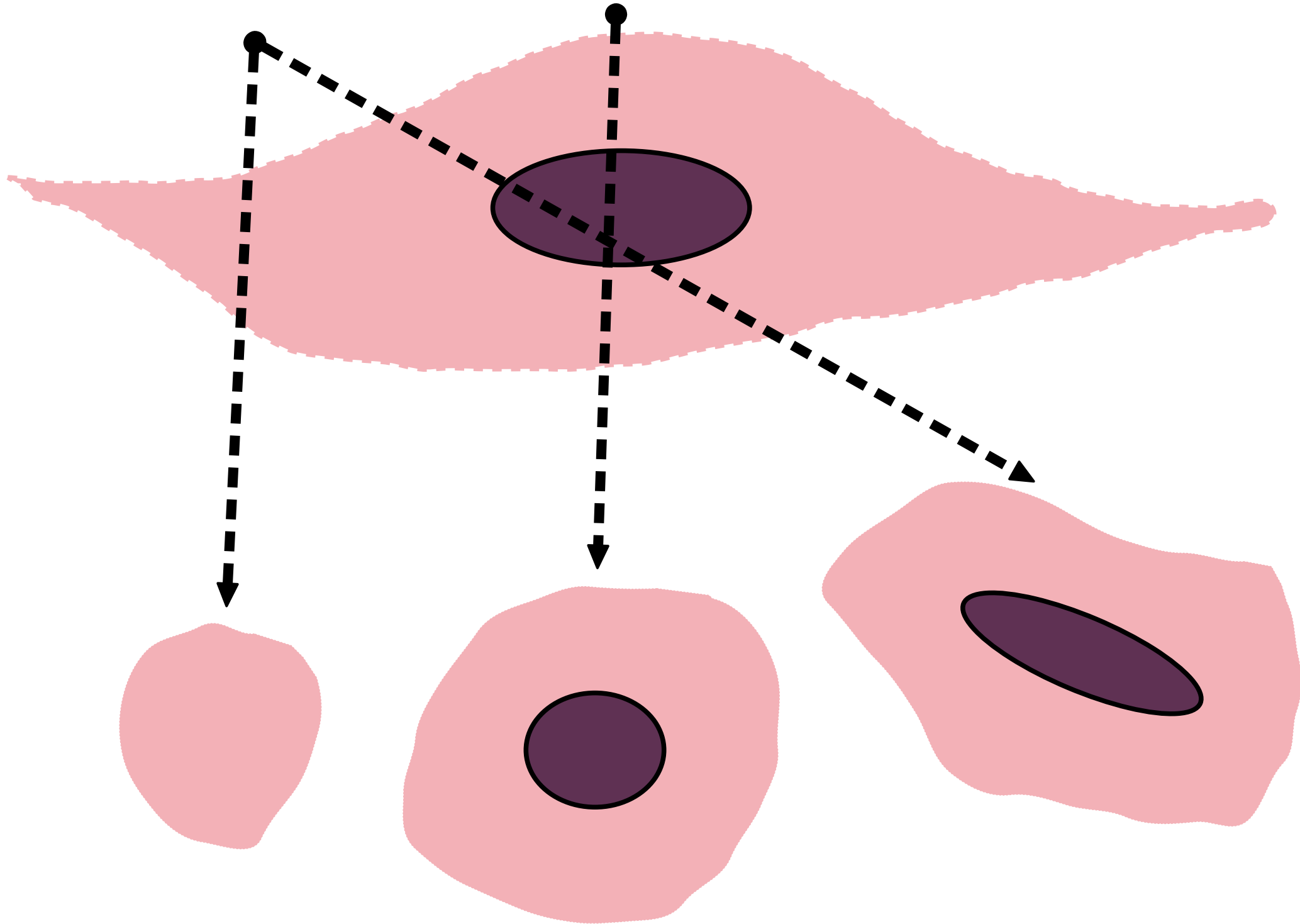
vascular bundle



Nuclei of fibroblasts in connective tissue

Medium magnification

Smooth muscle fibre



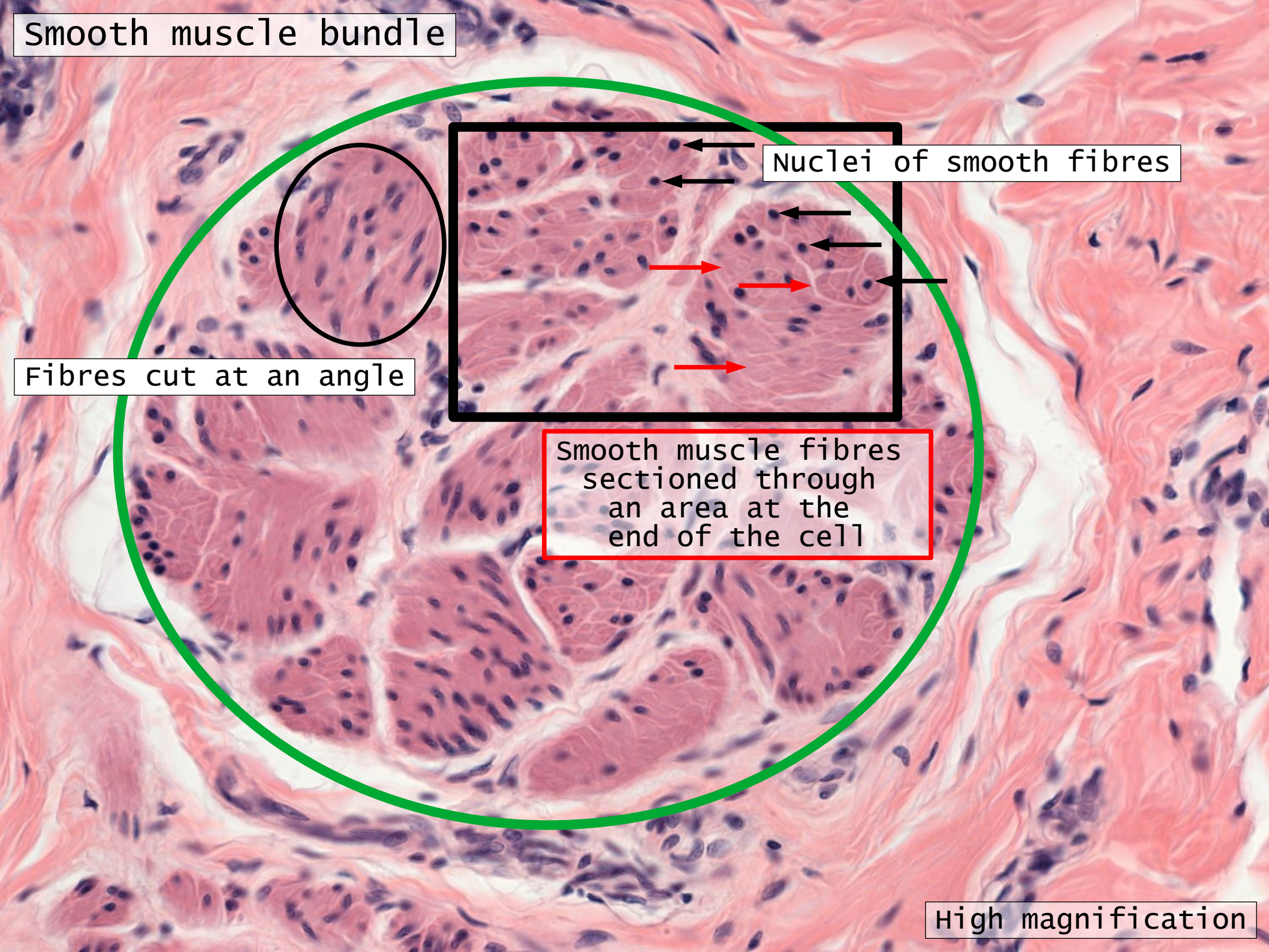
Smooth muscle bundle

Nuclei of smooth fibres

Fibres cut at an angle

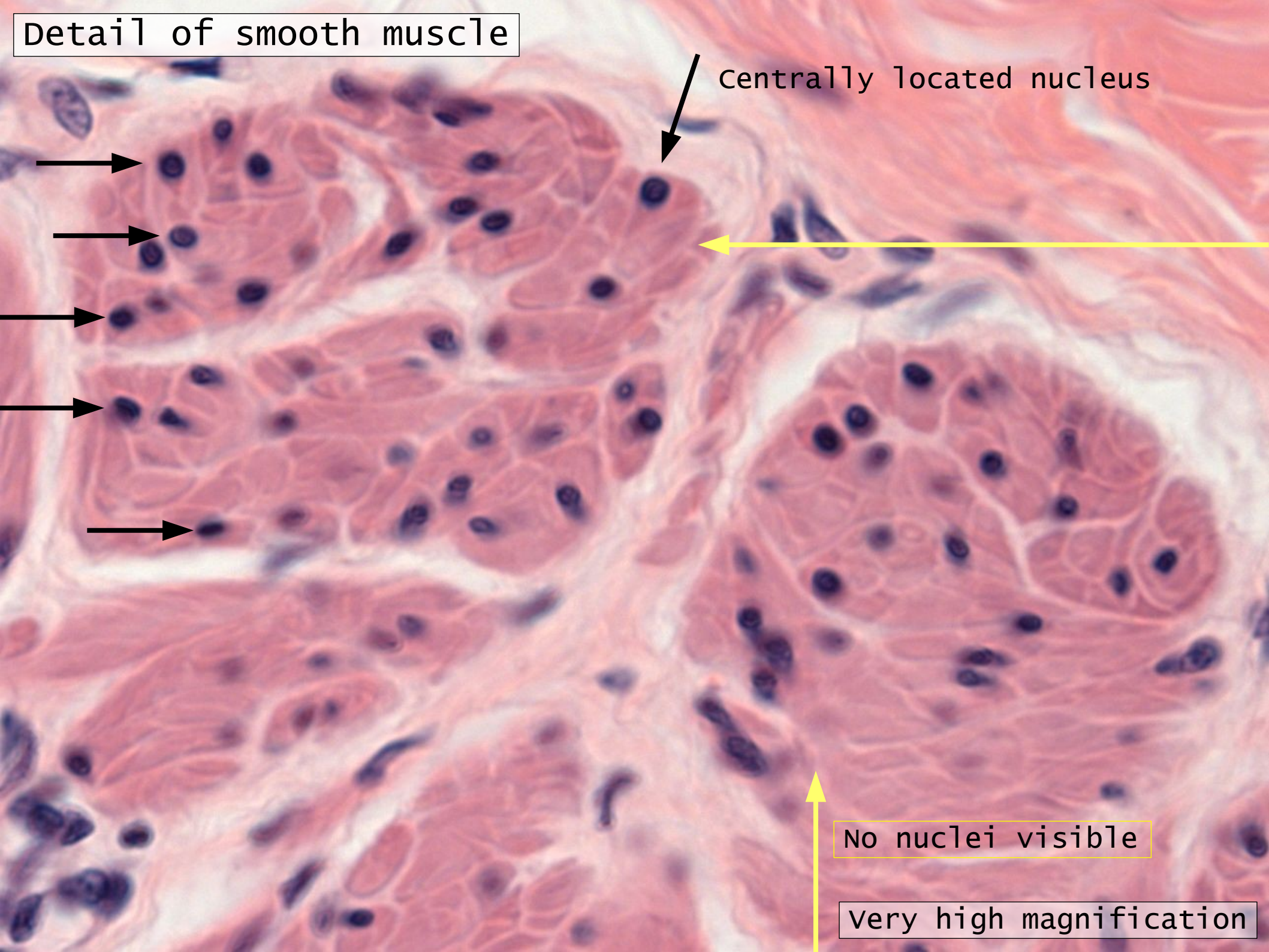
Smooth muscle fibres sectioned through an area at the end of the cell

High magnification



Detail of smooth muscle

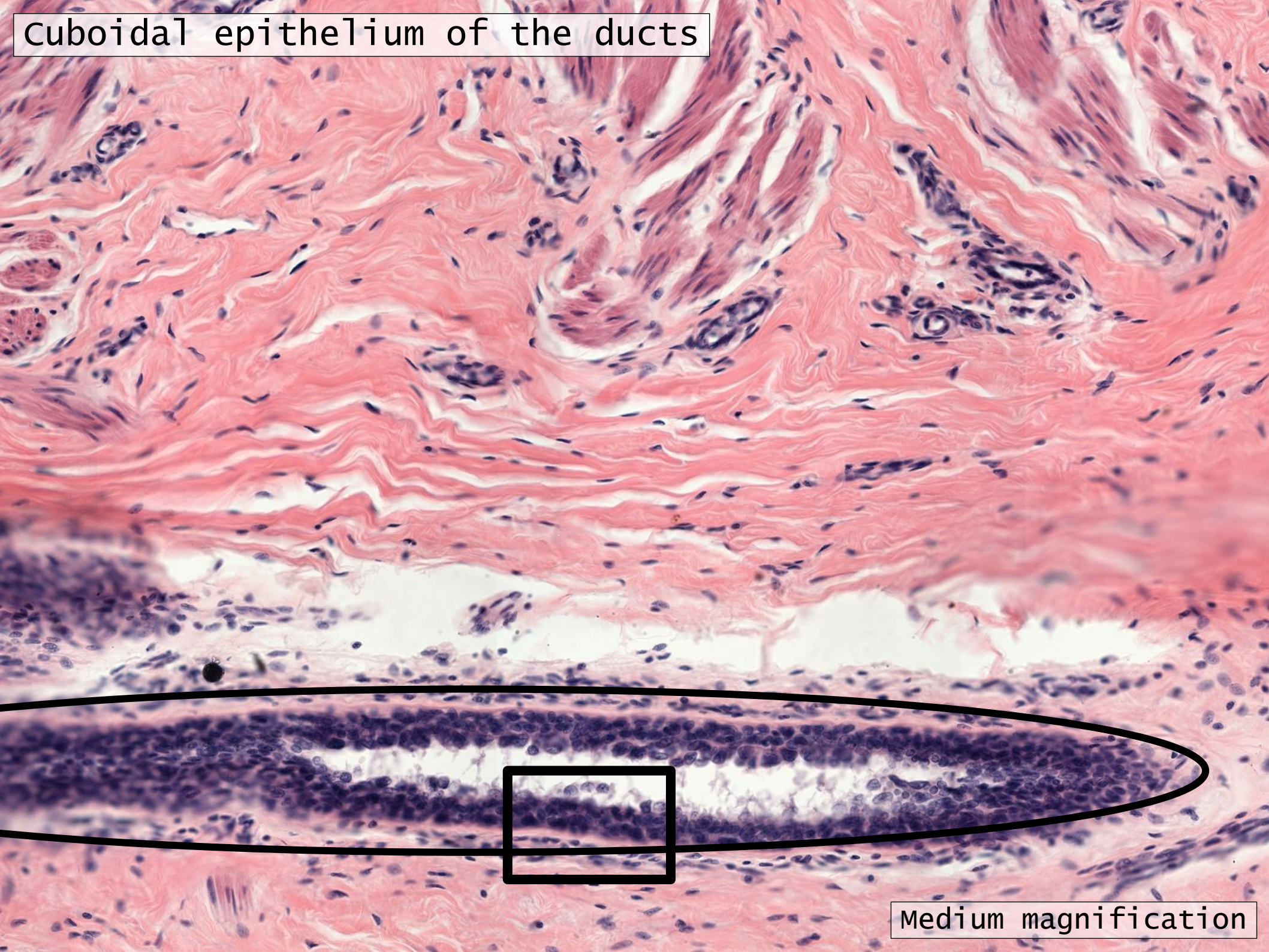
Centrally located nucleus



No nuclei visible

very high magnification

Cuboidal epithelium of the ducts



Medium magnification

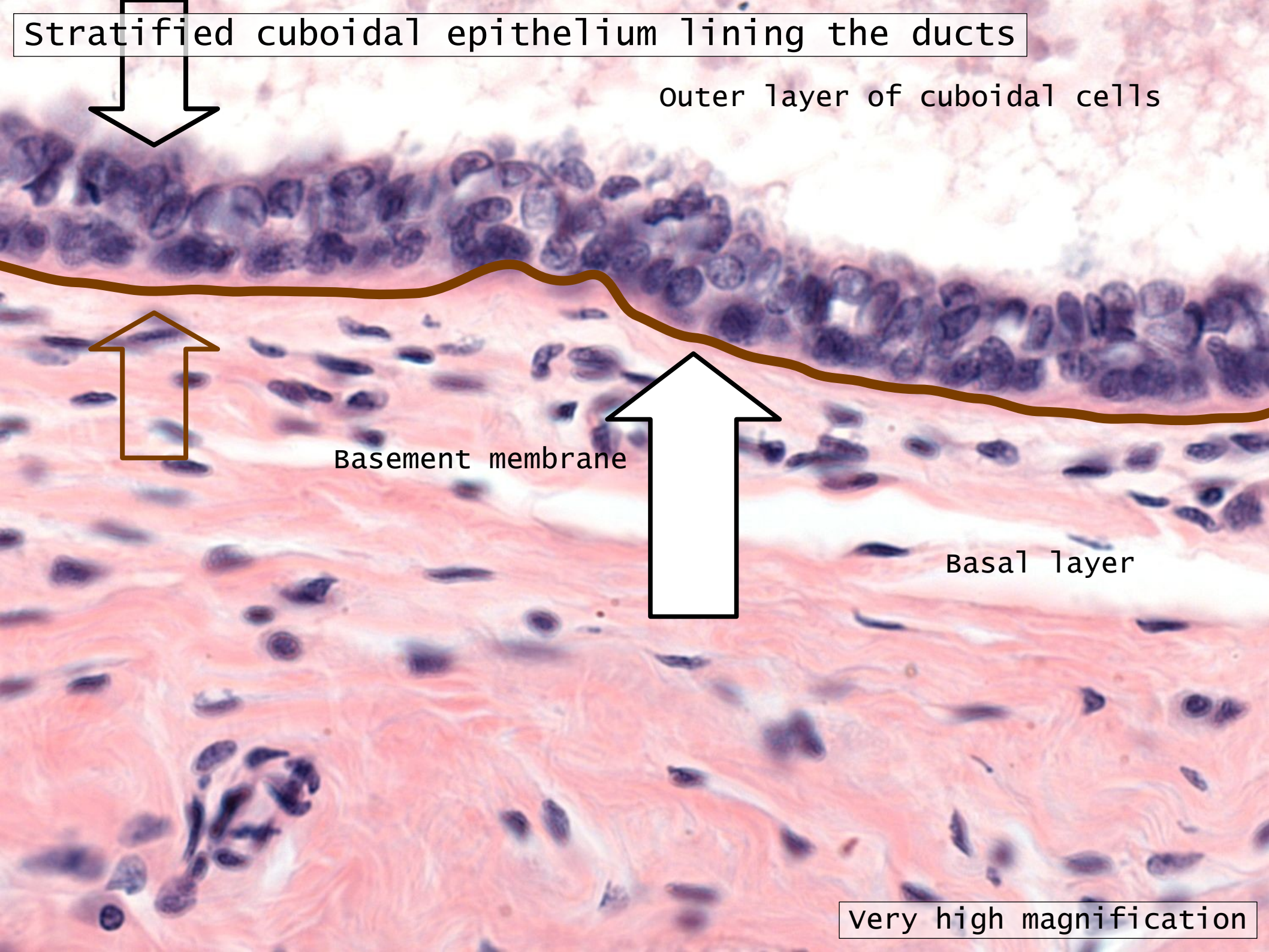
Stratified cuboidal epithelium lining the ducts

outer layer of cuboidal cells

Basement membrane

Basal layer

very high magnification



Completion

- You can work ahead
- On all GIT slides
- **Repeats**
 - Pancreas
 - Oesophagus
 - Liver

THE
END

